

## Association between ovarian endometrioma and ovarian reserve

Michio Kitajima<sup>1</sup>, Khaleque Newaz Khan<sup>2</sup>, Ayumi Harada<sup>1</sup>, Ken Taniguchi<sup>1</sup>, Tsuneo Inoue<sup>1</sup>, Masanori Kaneuchi<sup>1</sup>, Kiyonori Miura<sup>1</sup>, Hideaki Masuzaki<sup>1</sup>

<sup>1</sup>Department of Obstetrics and Gynecology, Nagasaki University Graduate School of BioMedical Sciences, 1-7-1 Sakamoto, Nagasaki, 852-8501, Japan, <sup>2</sup>Department of Obstetrics and Gynecology, Kyoto Prefectural University of Medicine, 465 Kajii-cho, Kamigyo-ku, Kyoto, 602-8566. Japan

### TABLE OF CONTENTS

1. Abstract
2. Introduction
3. The definition and the evaluation of ovarian reserve
4. The effects of endometrioma on ovarian reserve: pathogenic points of view
5. Ovarian reserve in women with endometriomas without surgery
6. Ovarian reserve in women had operated for endometriomas
  - 6.1. Surgery for endometriomas may damage residual normal cortex
  - 6.2. Controversies in assessment of surgical damage with ovarian reserve testing in women with endometriomas
  - 6.3. The effects of surgical methods on post-surgical ovarian reserve
  - 6.4. Confounding factors that affect post-surgical ovarian reserve
7. Conclusions and future perspective
8. References

### 1. ABSTRACT

Endometrioma is one of the main pathologies of endometriosis, though its pathogenesis still remains enigmatic. Ovarian reserve is defined as the number and quality of the follicles left in the ovary at any given time. The cause of infertility in women with endometriosis is multifactorial. Diminished ovarian reserve is major concern in women with endometriosis-associated infertility. Cystectomy for endometriomas could negatively impact on post-operative ovarian reserve. Some women had surgery for endometriomas suffer from poor ovarian response, which directly affects treatment results. In addition, endometriomas themselves may be a cause of diminished ovarian reserve. Destruction of normal histological structure in ovarian cortex may affect dormancy of primordial follicles. Therefore, determination of ovarian reserve may serve as an important role in the management of reproductive health of women with endometriosis. Although the knowledge on the physiology of follicular development and mechanism of maintenance of ovarian reserve are rapidly accumulating, results obtained by ovarian reserve testing after surgery should be carefully evaluated according to the time-points and selected test. Further investigation on this issue is warranted.

### 2. INTRODUCTION

Endometriosis affects 6–10% of women at reproductive age and may cause the disturbances on women's quality of life due to pain and infertility (1). The pathogenesis of the disease had long been a matter of debate and it is still not fully elucidated (2). Endometriosis mainly occurs in pelvic organ, such as peritoneum, ovary and recto-vaginal septum, the pathogenesis and clinical entity is different from each specific anatomical lesion (3). Ovarian endometrioma may be originated from adhesion between peritoneum and ovarian surface implants and the pseudo cyst may be formed by incessant bleeding from endometriotic lesions (4). In another view, endometrioma may be originated from metaplasia of invaginated ovarian surface epithelium (5). It has been shown that primordial follicles in ovarian cortex that constitute ovarian reserve exist as nests in superficial layer of ovarian cortex (6). As ovarian endometrioma may be formed just beneath of ovarian surface according to either fore-mentioned hypothesis, such as pseudo cyst formation or metaplasia of epithelial inclusion cyst, dormant or early growing follicles in ovarian cortex may be affected by formation and progression of ovarian endometriomas. Similarly, surgical intervention to ovarian endometriomas may be detrimental to residual normal ovarian cortical tissue. Recently,

large attentions had been paid on the risk of surgery on ovarian reserve in women with endometriomas. Many studies that evaluating the relationship between surgical intervention for endometriomas and post-operative ovarian reserve have been reported though the conclusion had not been reached. Confounding factors that affect the results of post-surgical ovarian reserve testing in women with endometriomas had not been well evaluated. On the other hand, ovarian endometrioma itself may be the cause of diminished ovarian reserve though clinical pictures of women with endometrioma without surgery had not been either elucidated. Therefore, in this review article, we tried to summarize the recent knowledge on the effect of endometriomas on ovarian reserve in pre- and post-surgery from its pathogenic point of view and surgery-related confounding variables that affect ovarian reserve testing to describe better clinical management on endometriosis.

### 3. THE DEFINITION AND THE EVALUATION OF OVARIAN RESERVE

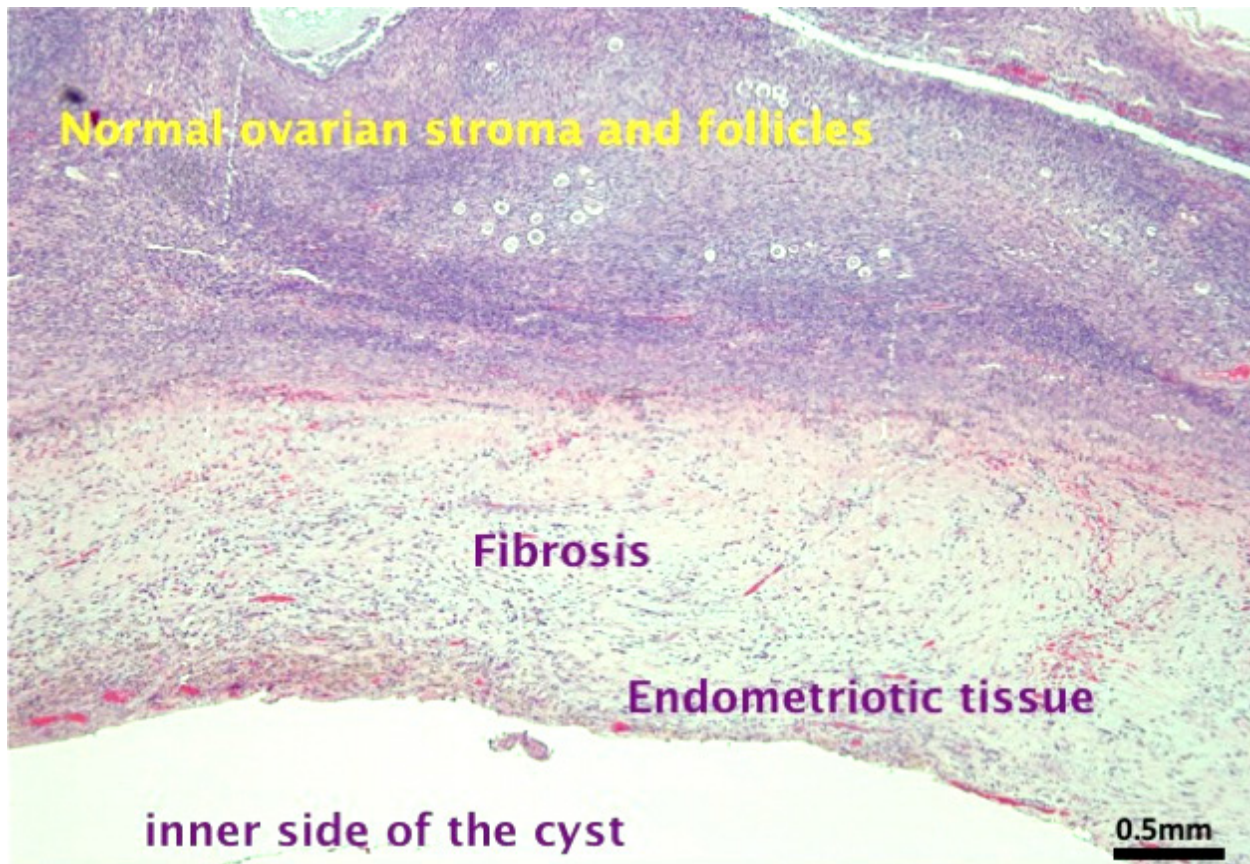
The term ovarian reserve is currently defined as the number and quality of the follicles left in the ovary at any given time (7). Several clinical tests to estimate ovarian reserve had been proposed. Endocrinological, ultrasonographic, and histological methods had been implicated, however, the accuracy of ovarian reserve testing to measure quality and quantity of remaining primordial follicles is still unclear (8). Serum follicle stimulating hormone (FSH) and estradiol (E2) levels in early follicular phase (i.e. cycle day 2–4) had long been utilized as markers for ovarian reserve classically, though the clinical value of this test is limited (9). Anti-Müllerian hormone (AMH), which is predominantly produced by the granulosa cells of the recruited preantral and early antral follicles from the nest of primordial follicle (AMH negative) until they become sensitive to gonadotrophin (10), now had got large popularity to predict ovarian reserve (11). Measurements of serum AMH may be superior to other markers of ovarian reserve, given its reliability and convenience, to estimate the number of growing follicles and ovarian reserve (12). Although some study suggested that serum AMH levels fluctuate little during the menstrual cycles, controversial results had been reported. Serum AMH levels may fluctuate especially with women with high basal AMH levels (the younger ovary pattern) comparing to those of women with low basal AMH levels (the ageing ovary pattern), and these fluctuations are randomly distributed during the cycles (13). Intra-individual variation of AMH throughout one cycle may be significantly and negatively associated with age (14). On the other hand, decrease in serum AMH levels can be observed after the exogenous gonadotropin treatment in infertile women, and it may be related

to the exhaustion of AMH producing early follicles by continuous stimulation (15). Prolonged ovarian suppression caused by long-term administration of oral contraceptives or GnRH agonist may lower serum AMH levels (16, 17). As these medications are often prescribed in women with endometriosis, one should take these issues into considerations. Ultrasonographic markers, such as antral follicle count (AFC) also have been introduced to clinical practice as popular ovarian reserve marker. AFC represents visible small antrum in early follicular phase and correlate well with age related decline of ovarian reserve (18). On the other hand, it may be difficult to assess the exact number of antral follicles of the cystic ovary, such as endometrioma, before cystectomy (19). In addition, measurement error may be present among different ultrasonographers who perform examinations. Although it had been reported to be correlated with AMH value (20), measuring objects are different from those of serum AMH levels. Therefore, these two major ovarian reserve markers may have different roles in its ability to predict ovarian reserve.

### 4. THE EFFECTS OF ENDOMETRIOMA ON OVARIAN RESERVE: PATHOGENIC POINTS OF VIEW

The pathogenesis of endometriomas had not been fully elucidated though several hypotheses had been proposed. Classically, retrograde menstruation into the pelvic cavity had been referred to as one of the major cause of endometriosis (21). Ovarian endometrioma may be the pseudo cyst that is formed by blood filled secretions from endometriotic lesion on ovarian surface adherent to broad ligament (pelvic peritoneum) (4). On the other hand, endometriomas may also be formed from metaplasia of epithelial lining of invaginated inclusion cyst (5). Recent observation suggested that endometriomas may also be formed from metaplastic change of corpus luteum cyst (22, 23). Interestingly, whatever the hypothesis, endometriomas may be developed in contiguity with surface ovarian cortex, which retain the pooling of primordial follicles that constitute ovarian reserve (Figure 1). Concerning the development of endometriotic lesion may evoke marked inflammation in surrounding tissue, the function of ovarian cortex as reservoir of dormant follicles may be affected by developing endometriomas. It is quite possible that detrimental effects on ovarian reserve by endometriomas may be accentuated by the surgical damage.

Ovarian cortex derived from ovaries with endometriomas showed decreased follicular density compared to those of contralateral healthy ovaries (24) or non-endometriotic benign ovarian cyst (25). In addition, ovaries with endometriomas showed significant fibrosis formation in ovarian



**Figure 1.** This photomicrograph is a representative finding of associations between the cyst wall of ovarian endometrioma and adjacent normal ovarian tissue. Hemorrhagic endometriotic lesion with dense fibrosis were constituted cyst wall, and numerous primordial follicles are present in normal ovarian cortex just beneath of the cyst wall. This histological sample was derived from woman had oophorectomy for ovarian endometrioma and full thickness sampling from inner surface of cyst wall to outer ovarian surface had been obtained. Original magnification \*20, H.E. staining.

cortex that is related to decrease of follicular density (24). These results support that the inflammation and transformation of normal cortical structure caused by development of endometriomas may affect physiological functions of adjacent ovarian cortex as follicular reservoir. Accelerated follicular recruitment and at the same time, increased atresia of early follicles were found in the ovarian cortex derived from ovaries with endometriomas comparing to those of contralateral intact ovaries (26). These results may indicate “burn-out” of ovarian reserve along with the development of endometriomas could be responsible for decreased fecundity in women with endometriosis.

### **5. OVARIAN RESERVE IN WOMEN WITH ENDOMETRIOMAS WITHOUT SURGERY**

The effect of endometriomas itself on the ovarian responsiveness that relate to ovarian reserve had been reported with several inconsistent results. In one study evaluated women with unilateral endometriomas, ovaries with disease showed lower

response to ovarian stimulation than contralateral healthy ovaries (27). However, recent study on infertile women with un-operated unilateral small endometriomas did not support difference in ovarian responsiveness (28, 29). Some women with untreated endometriomas showed decreased pre-surgical AMH levels, especially those with bilateral lesion, compared to control women without endometriosis or with other benign ovarian cysts (30, 31).

One study reported that severity of endometriosis might be correlated with the decline of ovarian reserve measured by serum AMH levels comparing to control women without endometriosis (32). On the other hand, in another study, endometriosis and ovarian endometrioma per se do not result in lowering AMH levels (33). AMH levels were decreased in women with previous endometrioma surgery independently of the presence of current endometriomas (34). Hence, it may warrant additional accumulation of clinical information to draw definitive conclusions on the relationship between endometriomas per se (without surgery) and ovarian reserve.



## 6. OVARIAN RESERVE IN WOMEN HAD OPERATED FOR ENDOMETRIOMAS

### 6.1. Surgery for endometriomas may damage residual normal cortex

Surgery is the mainstay of the diagnosis and treatment of endometriosis. Cystectomy is recommended for ovarian endometriomas larger than 3cm in terms of pain relief, recurrence rate and post-surgical fecundability (34). On the other hand, surgery may possess the risk of diminished ovarian reserve, which might affect post-surgical infertility treatment. Although some surgeons had reported excellent results (35, 36), cystectomy for endometrioma may cause unavoidable risk of surgical injury to residual normal ovarian tissue even with skilled hands (37). Interestingly, women with recurrent endometrioma after surgery showed better ovarian response during infertility treatment than women without recurrence (38). This report may suggest that surgical radicality may reduce recurrence rate though ovarian function may be sacrificed. Cystectomy for endometrioma may be more harmful than those for non-endometriotic benign ovarian cyst and the acute decline of AMH post-surgery in women with endometrioma may be related to the damage of the residual normal ovarian cortex (39).

### 6.2. Controversies in assessment of surgical damage with ovarian reserve testing in women with endometriomas

Several ovarian reserve testings had been utilized to evaluate the damage of surgery for endometriomas on residual normal ovarian cortex. The interpretation of the results may be dependent which test was utilized to assess the damage. When serum FSH had been considered as the evaluation factor, surgical damage to residual normal tissue may not correlate with serum FSH levels (40) Some report utilized serum inhibin B as the evaluation factor for post operative damage (41). Different ovarian reserve markers may bring different results after surgery. According to the clinical efficacy to predict ovarian response in ART settings comparing to other tests, fore-mentioned AMH and AFC can be regarded as most sensitive marker after the surgery for endometriomas though interpretation of the results should be made carefully (42). Post-operative AFC value had been evaluated by meta-analysis and systematic review, which revealed that surgery for endometrioma does not significantly affect ovarian reserve as evaluated by AFC (43). A lower AFC is present on the affected ovary both before and after surgery. Thus, surgical treatment for endometriomas may not affect the ovarian reserve than previously thought defined by AFC (43). In another report, serum AMH levels were significantly decreased after laparoscopic cystectomy while there were no

significant changes in other ovarian reserve tests (FSH, E2, AFC and ovarian volumes) (37, 44). On the other hand, one study reported that AFC is reduced in ovaries with endometrioma though the number of oocytes retrieved in IVF-ET after surgery is similar, suggesting that the AFC is underestimated and may be the consequence of an impaired ability to detect small follicles in the presence of an endometrioma (45).

According to the systematic review and meta-analysis, the existing literature supports an adverse effect of ovarian endometriomas on markers of ovarian reserve (46,47). Surgical removal of endometriomas may worsen ovarian reserve by removing healthy ovarian cortex or compromising blood flow to the ovary. Meta-analysis and systematic review showed that surgical excision of endometriomas acutely impairs serum AMH levels (48, 49) (Table 1); whether this represents progressive or long term impairment remains the subject of ongoing investigation (50–52).

### 6.3. The effects of surgical methods on post-surgical ovarian reserve

The choice of surgical methods for endometriomas (ablation or cystectomy) may influence the post surgical ovarian reserve. One prospective randomized study revealed that the ablation of cyst-wall may be more feasible than cystectomy in terms of preserving ovarian function (53). Another prospective randomized study utilizing the ablation with CO2 laser at second look laparoscopy after the irrigation and aspiration at primary laparoscopy and post-surgical GnRHa therapy for 3month (three-step procedure) did not show significant decline in post surgical serum AMH levels while one-step cystectomy showed significant decline in AMH levels (54). Another randomized controlled trial found that laparoscopic stripping of ovarian endometriotic cyst significantly decreases serum AMH levels and increases basal FSH levels independent of the method used to obtain hemostasis on the ovarian tissue (55). Recently, a study assessed AMH level after unilateral ovarian endometrioma cyst wall ablation using plasma energy showed immediate decrease followed by progressive increase of AMH level several months after the surgery, with good fertility outcomes (56). This surgical technique also showed significantly higher postoperative AFC and ovarian volume comparing to those of cystectomy (57). These studies implicate ablative surgery rather than cystectomy may be feasible in women need to preserve ovarian reserve for future fecundation.

For hemostatic technique during surgery, the suturing may be better hemostatic methods than bipolar coagulation in terms of protecting ovarian reserve (58). In another study, women with unilateral endometrioma had stripping without accessing a bipolar coagulation and performing an intra-cortical suture did not show

**Table 1.** Recent meta-analysis assessing the effects of ovarian endometriomas and its surgical treatment on ovarian reserve

Year	Author (Ref#)	The objective of meta-analysis	No of included study	No of pooled subjects	Outcome measure	Results
2015	Ding W, <i>et al.</i> (62)	Methods of hemostasis (suture or bipolar coagulation)	21	312	AMH, FSH, AFC at 3-month follow-up	bipolar coagulation vs. suture AMH↓ FSH↔ AFC↓
2015	Ata B, <i>et al.</i> (63)	Methods of hemostasis (BD, suturing, HS application)	6	213	AMH at 3month post surgery	BD vs. alternative methods AMH↓
2015	Hamdan M, <i>et al.</i> (47)	Endometrioma itself and its surgery on ART outcomes	33	928	LBR, CPR, MNOR, CR, MR, FR, IR, AFC	intact Eoma vs. no Eosis LBR, CPR↔ MNOR↓ CR↑ intact Eoma vs. Eosis without Eoma LBR, CPR, MNOR↔ AFC↓ treated Eoma vs. intact Eoma LBR, CPR, MNOR↔ FSH dose↑ treated Eoma vs. un-treated Eoma (contralateral) MNOR↓
2014	Muzii L, <i>et al.</i> (43)	Surgical treatment on ovarian reserve	13	597	AFC	un-treated Eoma vs. without Eoma (contralateral) AFC↓(but not statistically significant) treated Eoma vs. without Eoma (contralateral) AFC↓ before vs. after surgery AFC↔
2012	Somigliana E, <i>et al.</i> (48)	Surgical treatment on ovarian reserve	11	NA	AMH	9 studies AMH↓ bilateral vs. unilateral AMH↓
2012	Raffi F, <i>et al.</i> (49)	Surgical treatment on ovarian reserve	8	237	AMH	cystectomy for Eoma AMH↓

AMH, anti- Müllerian hormone; FSH, follicle stimulating hormone; AFC, antral follicle count; BD, bipolar dessication; HS, hemostatic sealant; LBR, live birth rate; CPR, clinical; pregnancy rate; MNOR, mean number of oocyte retrieved; CR, cancellation rate; MR, miscarriage rate; FR, fertilization rate; IR, implantation rate; Eosis, endometriosis; Eoma, endometrioma; NA, not applicable

statistically significant decreases in serum AMH levels after surgical excision of the cysts. These results suggest that an appropriate surgical technique, without the use of the bipolar coagulation of ovarian border, does not determine a significant reduction of ovarian reserve (59). However, other studies did not find any significant difference in the outcome of IVF or ovarian reserve marker between the two different methods of hemostasis (60, 61). Meta-analysis on the methods of hemostasis in the surgery with ovarian endometriomas had been reported, which concluded that usage of bipolar coagulation may deteriorate ovarian reserve (62, 63) (Table 1).

Recently, ultrasound-guided aspiration followed by ethanol sclerotherapy had been proposed as a conservative treatment before ART in women with

recurrent endometriomas. Infertility treatment outcome may not be negatively affected while this procedure may bring about lower recurrence rate comparing to those of aspiration alone (64, 65). The effect of this procedure on ovarian reserve had not been well determined. The experiments in rodent had been suggested that concomitant decline in ovarian reserve due to increased fibrosis along with reduction in cyst diameters (66).

#### 6.4. Confounding factors that affect post-surgical ovarian reserve

The factors that affect post-surgical decline in ovarian reserve had been evaluated in several reports. Age and laterality are significant contributors to the change of post-operative ovarian reserve marker (67).

Kwon SK *et al.* had been reported that irrespective of the type of cyst (endometriomas or other benign cyst) laterality is only significant factor predicting the rate of decline in AMH levels after cystectomy (68). Severity of endometriosis (by r-ASRM score) may predict the decline of post-operative serum AMH levels (69). In another study, the operation-related damage to the ovarian reserve was positively related to whether the endometriomas were bilateral, as well as to the cyst size (especially for cysts >7 cm), but was negatively related to the pre-operative serum AMH level. Age was a negative factor that affected the ovarian reserve in this study (70).

Most of the study revealed immediate reduction in serum AMH levels 1–3 months post-surgery. The decline of AMH may progressively persist at 6-month post cystectomy (71). Interestingly, Sugita *et al.* reported that decreased serum AMH levels immediately after cystectomy recovered at 12month post-surgery in about half of their study cohort. These results suggest that clinical factor(s) other than surgical damage may be attributed to persistent demise of ovarian reserve (51). One study reported that AFC decreased whereas ovarian volume and AMH levels did not negatively changed at 3 month after surgery (72). Another study also reported that serum AMH levels and AFC did not correlate each other at 6 month after surgery for endometriomas (73). These and pre-mentioned results may indicate that selection of test and time points should be taken into consideration when one to evaluate the damage of surgery for endometriomas.

## 7. CONCLUSIONS AND FUTURE PERSPECTIVE

From the current information summarized in this review, ovarian endometriomas per se may damage ovarian reserve, and cystectomy of endometriomas may cause greater damage to ovarian reserve compared with other benign ovarian cysts. The damage on ovarian reserve in affected ovary before surgery may be related to destruction of normal ovarian cortical structure. Results of ovarian reserve test in women with endometriomas without surgery may be related to severity of the endometriosis at the surgery, laterality of the disease. This information may implicate the damage may progress along with development and growth of endometriomas though its mechanism had not been fully delineated and clinical information on this issue yet to be elucidated. Further study on the relationship between tissue inflammation caused by development of endometriomas and the maintenance of dormancy of primordial follicles that directly relate to ovarian reserve may be needed.

On the other hand, the damage on ovarian reserve by surgery for endometriomas is unpredictable in most of the cases and some women suffer from diminished ovarian reserve after surgery. Inconsistent

results may be due to the limited ability of ovarian reserve testing to detect true surgical damage to residual normal ovary. The time points to perform ovarian reserve testing after surgery may be important to estimate the damage. Some specific factors relating to post-surgical ovarian reserve test, such as severity of the endometriosis at the surgery, laterality of the disease, size of the lesion, had been indicated. Ablative surgery rather than simple stripping technique may be feasible concerning ovarian reserve after surgery, however, additional data accumulation and consensus should be developed on the evaluation of the risk of different surgical methods on endometriomas.

Considering the pathogenesis of endometrioma and its putative effects on ovarian reserve, early diagnosis through a minimally invasive technique, followed by early ablative surgery whenever indicated, represents the management of choice to preserve ovarian reserve (4), though the efficacy of these strategy had not been well examined. Further research may be warranted to optimize the treatment strategy in women with endometrioma who need to preserve ovarian reserve and maintain consequent reproductive potentiality.

## 8. REFERENCES

1. B Eskenazi, ML Warner: Epidemiology of endometriosis. *Obstet Gynecol Clin North Am* 24, 235–258 (1997)  
DOI: 10.1016/S0889-8545(05)70302-8
2. RO Burney, LC Giudice: Pathogenesis and pathophysiology of endometriosis. *Fertil Steril* 98, 511–519 (2012)  
DOI: 10.1016/j.fertnstert.2012.06.029
3. M Nisolle, J Donnez: Peritoneal endometriosis, ovarian endometriosis, and adenomyotic nodules of the rectovaginal septum are three different entities. *Fertil Steril* 68, 585–596 (1997)  
DOI: 10.1016/S0015-0282(97)00191-X
4. I Brosens, S Gordts, P Puttemans, G Benagiano: Pathophysiology proposed as the basis for modern management of the ovarian endometrioma. *Reprod Biomed Online* 28, 232–238 (2014)  
DOI: 10.1016/j.rbmo.2013.09.024
5. J Donnez, M Nisolle, N Gillet, M Smets, S Bassil, F Casanas-Roux: Large ovarian endometriomas. *Hum Reprod* 11, 641–646 (1996)  
DOI: 10.1093/HUMREP/11.3.641
6. A Lass, R Silye, DC Abrams, T Krausz, O Hovatta, R Margara, RM Winston: Follicular

- density in ovarian biopsy of infertile women: a novel method to assess ovarian reserve. *Hum Reprod* 12, 1028–1031 (1997)  
DOI: 10.1093/humrep/12.5.1028
7. FJ Broekmans, J Kwee, DJ Hendriks, BW Mol, CB Lambalk: A systematic review of tests predicting ovarian reserve and IVF outcome. *Hum Reprod Update* 12, 685–718 (2006)  
DOI: 10.1093/humupd/dml034
  8. A Bukman, MJ Heineman: Ovarian reserve testing and the use of prognostic models in patients with subfertility. *Hum Reprod Update* 7, 581–590 (2001)  
DOI: 10.1093/humupd/7.6.581
  9. LF Bancsi, FJ Broekmans, BW Mol, JD Habbena, ER te Velde: Performance of basal follicle-stimulating hormone in the prediction of poor ovarian response and failure to become pregnant after *in vitro* fertilization: a meta-analysis. *Fertil Steril* 79, 1091–1100 (2003)  
DOI: 10.1016/S0015-0282(03)00078-5
  10. JA Visser, AP Themmen: Anti-Mullerian hormone and folliculogenesis. *Mol Cell Endocrinol* 234, 81–86 (2005)  
DOI: 10.1016/j.mce.2004.09.008
  11. C Weenen, JS Laven, AR Von Bergh, M Cranfield, NP Groome, JA Visser, P Kramer, BC Fauser, AP Themmen: Anti-Müllerian hormone expression pattern in the human ovary: potential implications for initial and cyclic follicle recruitment. *Mol Hum Reprod* 10, 77–83 (2004)  
DOI: 10.1093/molehr/gah015
  12. DB Seifer, DT MacLaughlin: Mullerian inhibiting substance is an ovarian growth factor of emerging clinical significance. *Fertil Steril* 88, 539–546 (2007)  
DOI: 10.1016/j.fertnstert.2007.02.014
  13. M Sowers, D McConnell, K Gast, H Zheng, B Nan, JD McCarthy, JF Randolph: Anti-Müllerian hormone and inhibin B variability during normal menstrual cycles. *Fertil Steril* 94, 1482–1486 (2010)  
DOI: 10.1016/j.fertnstert.2009.07.1674
  14. AOverbeek, FJ Broekmans, WJ Hehenkamp, ME Wijdeveld, J van Disseldorp, E van Dulmen-den Broeder, CB Lambalk: Intra-cycle fluctuations of anti-Müllerian hormone in normal women with a regular cycle: a re-analysis. *Reprod Biomed Online* 24, 664–669 (2012)  
DOI: 10.1016/j.rbmo.2012.02.023
  15. R Fanchin, LM Schonäuer, C Righini, N Frydman, R Frydman, J Taieb: Serum anti-Müllerian hormone dynamics during controlled ovarian hyperstimulation. *Hum Reprod* 18, 328–332 (2003)  
DOI: 10.1093/humrep/deg043
  16. S Kallio, J Puurunen, A Ruokonen, T Vaskivuo, T Pilttonen, JS Tapanainen: Antimüllerian hormone levels decrease in women using combined contraception independently of administration route. *Fertil Steril* 99, 1305–1310 (2013)  
DOI: 10.1016/j.fertnstert.2012.11.034
  17. CP Hagen, K Sørensen, RA Anderson, A Juul: Serum levels of antimüllerian hormone in early maturing girls before, during, and after suppression with GnRH agonist. *Fertil Steril* 98, 1326–1330 (2012)  
DOI: 10.1016/j.fertnstert.2012.07.1118
  18. GJ Scheffer, FJ Broekmans, M Dorland, JD Habbema, CW Looman, ER te Velde: Antral follicle counts by transvaginal ultrasonography are related to age in women with proven natural fertility. *Fertil Steril* 72, 845–851 (1999)  
DOI: 10.1016/S0015-0282(99)00396-9
  19. A Maheswari, P Fowler, S Bhattacharya: Assessment of ovarian reserve—should we perform tests of ovarian reserve routinely? *Hum Reprod* 21, 2729–2735 (2006)  
DOI: 10.1093/humrep/del188
  20. KR Hansen, GM Hodnett, N Knowlton, LB Craig: Correlation of ovarian reserve tests with histologically determined primordial follicle number. *Fertil Steril* 95, 170–175 (2011)  
DOI: 10.1016/j.fertnstert.2010.04.006
  21. JA Sampson: Peritoneal endometriosis due to menstrual dissemination of endometrial tissue into the peritoneal cavity. *Am J Obstet Gynecol* 14, 442–469 (1927)  
DOI: 10.1016/S0002-9378(15)30003-X
  22. C Nezhat, F Nezhat, C Nezhat, DS Seidman: Classification of endometriosis. Improving the classification of endometriotic ovarian cysts. *Hum Reprod* 9:2212–2213 (1994).  
DOI: 10.1093/oxfordjournals.humrep.a138423

23. P Vercellini, E Somigliana, P Vigano, A Abbiati, G Barbara, L Fedele: 'Blood On The Tracks' from corpora lutea to endometriomas. *BJOG* 116, 366–371 (2009)  
DOI: 10.1111/j.1471-0528.2008.02055.x
24. M Kitajima, S Defrère, MM Dolmans, S Colette, J Squifflet, A Van Langendonck, J Donnez: Endometriomas as a possible cause of reduced ovarian reserve in women with endometriosis. *Fertil Steril* 96, 685–691 (2011)  
DOI: 10.1016/j.fertnstert.2011.06.064
25. M Kuroda, K Kuroda, A Arakawa, Y Fukumura, M Kitade, I Kikuchi, J Kumakiri, S Matsuoka, IA Brosens, JJ Brosens, S Takeda, T Yao: Histological assessment of impact of ovarian endometrioma and laparoscopic cystectomy on ovarian reserve. *J Obstet Gynaecol Res* 38, 1187–1193 (2012)  
DOI: 10.1111/j.1447-0756.2012.01845.x
26. M Kitajima, MM Dolmans, O Donnez, H Masuzaki, M Soares, J Donnez. Enhanced follicular recruitment and atresia in cortex derived from ovaries with endometriomas. *Fertil Steril* 101, 1031–1037 (2014)  
DOI: 10.1016/j.fertnstert.2013.12.049
27. E Somigliana, M Infantino, F Benedetti, M Arnoldi, G Calanna, G Ragni: The presence of ovarian endometriomas is associated with a reduced responsiveness to gonadotropins. *Fertil Steril* 86, 192–196 (2006)  
DOI: 10.1016/j.fertnstert.2005.12.034
28. I Esinler, G Bozdog, I Arikan, B Demir, H Yarali: Endometriomas  $\leq 3$  cm in diameter per se does not affect ovarian reserve in intracytoplasmic sperm injection cycles. *Gynecol Obstet Invest* 74, 261–264 (2012)  
DOI: 10.1159/000339630
29. L Benaglia, R Pasin, E Somigliana, P Vercellini, G Ragni, L Fedele: Unoperated ovarian endometriomas and responsiveness to hyperstimulation. *Hum Reprod* 26, 1356–1361 (2011)  
DOI: 10.1093/humrep/der097
30. YM Hwu, FS Wu, SH Li, FJ Sun, MH Lin, RK Lee: The impact of endometrioma and laparoscopic cystectomy on serum anti-Müllerian hormone levels. *Reprod Biol Endocrinol* 9, 80 (2011)  
DOI: 10.1186/1477-7827-9-80
31. E Somigliana, MA Marchese, MP Frattaruolo, N Berlanda, L Fedele, P Vercellini: Serum anti-müllerian hormone in reproductive aged women with benign ovarian cysts. *Eur J Obstet Gynecol Reprod Biol* 180:142–147 (2014)  
DOI: 10.1016/j.ejogrb.2014.06.009
32. A Pacchiarotti, P Frati, GN Milazzo, A Catalano, V Gentile, M Moscarini: Evaluation of serum anti-Müllerian hormone levels to assess the ovarian reserve in women with severe endometriosis. *Eur J Obstet Gynecol Reprod Biol* 172, 62–64 (2014)  
DOI: 10.1016/j.ejogrb.2013.10.003
33. I Streuli, D de Ziegler, V Gayet, P Santulli, G Bijaoui, J de Mouzon, C Chapron: In women with endometriosis anti-Müllerian hormone levels are decreased only in those with previous endometrioma surgery. *Hum Reprod* 27, 3294–3303 (2012)  
DOI: 10.1093/humrep/des274
34. GA Dunselman, N Vermeulen, C Becker, C Calhaz-Jorge, T D'Hooghe, B De Bie, O Heikinheimo, AW Horne, L Kiesel, A Nap, A Prentice, E Saridogan, D Soriano, W Nelen; European Society of Human Reproduction and Embryology. ESHRE guideline: management of women with endometriosis: *Hum Reprod* 29, 400–412 (2014)  
DOI: 10.1093/humrep/det457
35. M Canis, JL Pouly, S Tamburro, G Mage, A Wattiez, MA Bruhat: Ovarian response during IVF-embryo transfer cycles after laparoscopic ovarian cystectomy for endometriotic cysts of  $>3$  cm in diameter. *Hum Reprod* 16, 2583–2586 (2001)  
DOI: 10.1093/humrep/16.12.2583
36. J Donnez, JC Lousse, P Jadoul, O Donnez, J Squifflet: Laparoscopic management of endometriomas using a combined technique of excisional (cystectomy) and ablative surgery. *Fertil Steril* 94, 28–32 (2010)  
DOI: 10.1016/j.fertnstert.2009.02.065
37. CP Biacchiardi, LD Piane, M Camanni, F Deltetto, EM Delpiano, GL Marchino, G Gennarelli, A Revelli: Laparoscopic stripping of endometriomas negatively affects ovarian follicular reserve even if performed by experienced surgeons. *Reprod Biomed Online* 23, 740–746 (2011)  
DOI: 10.1016/j.rbmo.2011.07.014
38. E Somigliana, L Benaglia, P Vercellini, A Paffoni, G Ragni, L Fedele: Recurrent endometrioma and ovarian reserve:



- biological connection or surgical paradox? *Am J Obstet Gynecol* 204, 529.e1–5 (2011)  
DOI: 10.1016/j.ajog.2011.01.053
39. M Kitajima, KN Khan, K Hiraki, T Inoue, A Fujishita, H Masuzaki: Changes in serum anti-Müllerian hormone levels may predict damage to residual normal ovarian tissue after laparoscopic surgery for women with ovarian endometrioma. *Fertil Steril* 95, 2589–2591.e1 (2011)  
DOI: 10.1016/j.fertnstert.2011.01.036
40. J Shi, J Leng, Q Cui, J Lang: Follicle loss after laparoscopic treatment of ovarian endometriotic cysts. *Int J Gynaecol Obstet* 115, 277–281 (2011)  
DOI: 10.1016/j.ijgo.2011.07.026
41. M Coric, T Goluzza, J Juras: Inhibin B for assessment of ovarian reserve after laparoscopic treatment of ovarian endometriomas. *Int J Gynaecol Obstet* 116, 169–170 (2012)  
DOI: 10.1016/j.ijgo.2011.09.014
42. L Muzii, AA Luciano, E Zupi, PB Panici: Effect of surgery for endometrioma on ovarian function: a different point of view. *J Minim Invasive Gynecol* 21, 531 (2014)  
DOI: 10.1016/j.jmig.2014.03.022
43. L Muzii, C Di Tucci, M Di Felicianantonio, C Marchetti, G Perniola, PB Panici: The effect of surgery for endometrioma on ovarian reserve evaluated by antral follicle count: a systematic review and meta-analysis. *Hum Reprod* 29, 2190–2198 (2014)  
DOI: 10.1093/humrep/deu199
44. WK Jang, SY Lim, JC Park, KR Lee, A Lee, JH Rhee: Surgical impact on serum anti-Müllerian hormone in women with benign ovarian cyst: A prospective study. *Obstet Gynecol Sci* 57, 121–127 (2014)  
DOI: 10.5468/ogs.2014.57.2.121
45. ML Lima, Martins WP, Coelho Neto MA, Nastri CO, Ferriani RA, Navarro PA. Assessment of ovarian reserve by antral follicle count in ovaries with endometrioma. *Ultrasound Obstet Gynecol* 46, 239–42 (2015)  
DOI: 10.1002/uog.14763
46. G Legendre, L Catala, C Morinière, C Lacoëuille, F BouSSION, L Sentilhes, P Descamps: Relationship between ovarian cysts and infertility: what surgery and when? *Fertil Steril* 101, 608–614 (2014)  
DOI: 10.1016/j.fertnstert.2014.01.021
47. M Hamdan, G Dunselman, TC Li, Y Cheong: The impact of endometrioma on IVF/ICSI outcomes: a systematic review and meta-analysis. *Hum Reprod Update* 21, 809–825 (2015)  
DOI: 10.1093/humupd/dmv035
48. E Somigliana, N Berlanda, L Benaglia, P Viganò, P Vercellini, L Fedele: Surgical excision of endometriomas and ovarian reserve: a systematic review on serum antimüllerian hormone level modifications. *Fertil Steril* 98:1531–1538 (2012)  
DOI: 10.1016/j.fertnstert.2012.08.009
49. F Raffi, M Metwally, S Amer: The impact of excision of ovarian endometrioma on ovarian reserve: a systematic review and meta-analysis. *J Clin Endocrinol Metab* 97, 3146–3154 (2012)  
DOI: 10.1210/jc.2012-1558
50. DK Shah, RB Mejia, DI Lebovic: Effect of surgery for endometrioma on ovarian function. *J Minim Invasive Gynecol* 21, 203–209 (2014)  
DOI: 10.1016/j.jmig.2013.09.012
51. A Sugita, A Iwase, M Goto, T Nakahara, T Nakamura, M Kondo, S Osuka, M Mori, A Saito, F Kikkawa: One-year follow-up of serum antimüllerian hormone levels in patients with cystectomy: are different sequential changes due to different mechanisms causing damage to the ovarian reserve? *Fertil Steril* 100, 516–522.e3 (2013)  
DOI: 10.1016/j.fertnstert.2013.03.032
52. M Vignali, M Mabrouk, E Ciocca, G Alabiso, A Barbasetti di Prun, D Gentilini, M Busacca: Surgical excision of ovarian endometriomas: Does it truly impair ovarian reserve? Long term anti-Müllerian hormone (AMH) changes after surgery. *J Obstet Gynaecol Res* 41, 1773–1778 (2015)  
DOI: 10.1111/jog.12830
53. T Var, S Batioglu, E Tonguc, I Kahyaoglu: The effect of laparoscopic ovarian cystectomy versus coagulation in bilateral endometriomas on ovarian reserve as determined by antral follicle count and ovarian volume: a prospective randomized study. *Fertil Steril* 95, 2247–2250 (2011)  
DOI: 10.1016/j.fertnstert.2011.03.078

54. D Tsolakidis, G Pados, D Vavilis, D Athanatos, T Tsalikis, A Giannakou, BC Tarlatzis: The impact on ovarian reserve after laparoscopic ovarian cystectomy versus three-stage management in patients with endometriomas: a prospective randomized study. *Fertil Steril* 94:71–77 (2010)  
DOI: 10.1016/j.fertnstert.2009.01.138
55. S Ferrero, PL Venturini, DJ Gillott, V Remorgida, U Leone Roberti Maggiore: Hemostasis by bipolar coagulation versus suture after surgical stripping of bilateral ovarian endometriomas: a randomized controlled trial. *J Minim Invasive Gynecol* 19, 722–730 (2012)  
DOI: 10.1016/j.jmig.2012.08.001
56. H Roman, M Bubenheim, M Auber, L Marpeau, L Puscasiu. Antimüllerian hormone level and endometrioma ablation using plasma energy. *JSL* 18, pii: e2014.0.0002 (2014)
57. H Roman, M Auber, C Mokdad, C Martin, A Diguët, L Marpeau, N Bourdel: Ovarian endometrioma ablation using plasma energy versus cystectomy: a step toward better preservation of the ovarian parenchyma in women wishing to conceive. *Fertil Steril* 96, 1396–1400 (2011)  
DOI: 10.1016/j.fertnstert.2011.09.045
58. T Song, WY Kim, KW Lee, KH Kim: Effect on ovarian reserve of hemostasis by bipolar coagulation versus suture during laparoendoscopic single-site cystectomy for ovarian endometriomas. *J Minim Invasive Gynecol* 22, 415–420 (2015)  
DOI: 10.1016/j.jmig.2014.11.002
59. P Litta, G D’Agostino, L Conte, C Saccardi, V Cela, S Angioni, M Plebani : Anti-Müllerian hormone trend after laparoscopic surgery in women with ovarian endometrioma. *Gynecol Endocrinol* 29, 452–454 (2013)  
DOI: 10.3109/09513590.2012.758704
60. A Takashima, N Takeshita, K Otaka, T Kinoshita: Effects of bipolar electrocoagulation versus suture after laparoscopic excision of ovarian endometrioma on the ovarian reserve and outcome of *in vitro* fertilization. *J Obstet Gynaecol Res* 39, 1246–1252 (2013)  
DOI: 10.1111/jog.12056
61. C Tanprasertkul, S Ekarattanawong, O Sreshthaputra, T Vutyavanich: Impact of hemostasis methods, electrocoagulation versus suture, in laparoscopic endometriotic cystectomy on the ovarian reserve: a randomized controlled trial. *J Med Assoc Thai* 97 Suppl 8, S95–101 (2014)
62. W Ding, M Li, Y Teng: The impact on ovarian reserve of haemostasis by bipolar coagulation versus suture following surgical stripping of ovarian endometrioma: a meta-analysis. *Reprod Biomed Online* 30, 635–642 (2015)  
DOI: 10.1016/j.rbmo.2015.02.012
63. B Ata, E Turkgeldi, A Seyhan, B Urman: Effect of hemostatic method on ovarian reserve following laparoscopic endometrioma excision; comparison of suture, hemostatic sealant, and bipolar desiccation. A systematic review and meta-analysis. *J Minim Invasive Gynecol* 22, 363–372 (2015)  
DOI: 10.1016/j.jmig.2014.12.168
64. MY Chang, CL Hsieh, CS Shiau, TT Hsieh, RD Chiang, CH Chan: Ultrasound-guided aspiration and ethanol sclerotherapy (EST) for treatment of cyst recurrence in patients after previous endometriosis surgery: analysis of influencing factors using a decision tree. *J Minim Invasive Gynecol* 20, 595–603 (2013)  
DOI: 10.1016/j.jmig.2013.03.004
65. KH Lee, CH Kim, YJ Lee, SH Kim, HD Chae, BM Kang: Surgical resection or aspiration with ethanol sclerotherapy of endometrioma before *in vitro* fertilization in infertile women with endometrioma. *Obstet Gynecol Sci* 57, 297–303 (2014)  
DOI: 10.5468/ogs.2014.57.4.297
66. R Atilgan, ZS Ozkan, T Kuloglu, N Kocaman, M Baspinar, B Can, M Şimşek, E Sapmaz: Impact of intracystic ethanol instillation on ovarian cyst diameter and adjacent ovarian tissue. *Eur J Obstet Gynecol Reprod Biol* 174, 133–136 (2014)  
DOI: 10.1016/j.ejogrb.2013.12.019
67. S Alborzi, P Keramati, M Younesi, A Samsami, N Dadras: The impact of laparoscopic cystectomy on ovarian reserve in patients with unilateral and bilateral endometriomas. *Fertil Steril* 101, 427–434 (2014)  
DOI: 10.1016/j.fertnstert.2013.10.019
68. SK Kwon, SH Kim, SC Yun, DY Kim, HD Chae, CH Kim, BM Kang: Decline of serum antimüllerian hormone levels

after laparoscopic ovarian cystectomy in endometrioma and other benign cysts: a prospective cohort study. *Fertil Steril* 101, 435–441 (2014)  
DOI: 10.1016/j.fertnstert.2013.10.043

69. W Hirokawa, A Iwase, M Goto, S Takikawa, Y Nagatomo, T Nakahara, B Bayasula, T Nakamura, S Manabe, F Kikkawa: The post-operative decline in serum anti-Mullerian hormone correlates with the bilaterality and severity of endometriosis. *Hum Reprod* 26, 904–910 (2011)  
DOI: 10.1093/humrep/der006
70. Y Chen, H Pei, Y Chang, M Chen, H Wang, H Xie, S Yao: The impact of endometrioma and laparoscopic cystectomy on ovarian reserve and the exploration of related factors assessed by serum anti-Mullerian hormone: a prospective cohort study. *J Ovarian Res* 26, 7, 108 (2014)
71. Celik HG, Dogan E, Okyay E, Ulukus C, Saatli B, Uysal S, Koyuncuoglu M. Effect of laparoscopic excision of endometriomas on ovarian reserve: serial changes in the serum antimüllerian hormone levels. *Fertil Steril* 97, 1472–1478 (2012)  
DOI: 10.1016/j.fertnstert.2012.03.027
72. CM Ercan, NK Duru, KE Karasahin, H Coksuer, M Dede, I Baser: Ultrasonographic evaluation and anti-mullerian hormone levels after laparoscopic stripping of unilateral endometriomas. *Eur J Obstet Gynecol Reprod Biol* 158, 280–284 (2011)  
DOI: 10.1016/j.ejogrb.2011.04.043
73. G Uncu, I Kasapoglu, K Ozerkan, A Seyhan, A Oral Yilmaztepe, B Ata: Prospective assessment of the impact of endometriomas and their removal on ovarian reserve and determinants of the rate of decline in ovarian reserve. *Hum Reprod* 28, 2140–2145 (2013)  
DOI: 10.1093/humrep/det123

**Abbreviations:** FSH: follicle stimulating hormone; AMH: anti-Müllerian hormone; AFC: antral follicle count; TGF: transforming growth factor; MIS: Müllerian-inhibiting substance; ART: assisted reproductive technology; IVF-ET: *in vitro* fertilization and embryo transfer; GnRH: gonadotropin releasing hormone; ASRM: American society for reproductive medicine

**Key Words** Ovarian Endometrioma, Ovarian Reserve, Surgery, Review

**Send correspondence to:** Michio Kitajima, 1-7-1 Sakamoto, Nagasaki, 852-8501, Japan, Tel: 81-95-819-7363, Fax: 81-95-819-7365, E-mail: m-kita@nagasaki-u.ac.jp