[Frontiers in Bioscience 9, 1483-1499, May 1, 2004]

TRANSVERSE MYELITIS: PATHOGENESIS, DIAGNOSIS AND TREATMENT

Chitra Krishnan [1], Adam I. Kaplin [2], Deepa M. Deshpande [1], Carlos A. Pardo [1] and Douglas A. Kerr [1]

[1] Department of Neurology, Johns Hopkins Transverse Myelitis Center, 600 N. Wolfe Street Pathology 627C, Baltimore MD 21287-6965, [2] Department of Psychiatry and Behavioral Sciences, Johns Hopkins University School of Medicine, Osler 320, 600 N. Wolfe Street, Baltimore, MD 21287-5371

TABLE OF CONTENTS

1. Abstract
2. Introduction
3. The spectrum of neuroimmunologic disorders
4. History of TM
5. Definition of transverse myelitis
- *5.1. Criteria of TM*
- *5.2. Evaluation of acute myelopathies*
- *5.3. Differential diagnoses/non-inflammatory myelopathies*
- *5.4. Discrimination from multiple sclerosis*

6. The natural history of tm
- *6.1. Epidemiology and clinical presentation of tm*
- *6.2. Monophasic vs. recurrent TM*
- *6.3. Prognosis*

7. Immunopathogenesis of TM
- *7.1. General pathology of TM*
- *7.2. Immunopathogenesis of TM*

8. Treatment of TM
- *8.1. Intravenous steroids*
- *8.2. Plasma exchange*
- *8.3. Other immunomodulatory treatment*
- *8.4. Long term management*

9. Speculations on future treatment of TM
10. Conclusions
11. Acknowledgements
12. References

1. ABSTRACT

Transverse Myelitis (TM) is a clinical syndrome in which an immune-mediated process causes neural injury to the spinal cord, resulting in varying degrees of weakness, sensory alterations and autonomic dysfunction. TM may exist as part of a multi-focal CNS disease (e.g. MS), multi-systemic disease (e.g. systemic lupus erythematosus), or as an isolated, idiopathic entity. In this article, we will summarize recent classification and diagnostic schemes (1), which provide a framework for the acute management of patients with TM. Additionally, we will review current concepts on the natural history, immunopathogenesis and treatment strategies for patients with TM.

2. INTRODUCTION

TM is a rare syndrome with an incidence of between 1 and 8 new cases per million people per year (2). TM is characterized by focal inflammation within the spinal cord and clinical manifestations are due to resultant neural dysfunction of motor, sensory and autonomic pathways within and passing through the inflamed area. There is often a clearly defined rostral border of sensory dysfunction and evidence of acute inflammation demonstrated by a spinal MRI and lumbar puncture. When the maximal level of deficit is reached, approximately 50% of patients have lost all movements of their legs, virtually all patients have some degree of bladder dysfunction, and 80-94% of patients have numbness, paresthesias or band like dysesthesias (2-7). Autonomic symptoms consist variably of increased urinary urgency, bowel or bladder incontinence, difficulty or inability to void, incomplete evacuation or bowel constipation and sexual dysfunction (8). Like MS (9), TM is the clinical manifestation of a variety of disorders, with distinct presentations and pathologies (10). Recently, we proposed a diagnostic and classification scheme which has defined TM as either idiopathic or associated with a known inflammatory disease (i.e. multiple sclerosis, systemic lupus erythematosus, Sjogren's syndrome, or neurosarcoidosis) (1). Patients with TM should be offered immunomodulatory treatment such as steroids and plasmapheresis though there is no consensus as to the most appropriate strategy yet. Most TM patients have monophasic disease, while up to 20% will have recurrent inflammatory episodes within the spinal cord (JHTMC case series, 11, 12).

Table 1. Spectrum of Neuroimmunologic Disorders

Disorder	Abbreviation	References
Muscle		
Polymositis	PM	27
Dermatomyositis	DM	107
Neuromuscular Junction		
Myasthenia gravis	MG	25
Peripheral Nerve		
Chronic Inflammatory Demyelinating Polyneuropathy	CIDP	108, 109
Acute Inflammatory Demyelinating Polyneuropathy	AIDP/GBS	13, 79
Spinal Cord		
Transverse myelitis	TM/ATM	1, 3, 19, 36
Tropical spastic paraparesis	TSP/HAM	28, 29
Stiff person syndrome	SPS	24
Spinal Cord and Optic Nerve		
Neuromyelitis optica	NMO	26, 101
Optic Nerve		
Optic neuritis	ON	110
Brain and Spinal Cord		
Multiple Sclerosis	MS	9
Paraneoplastic encephalomyelitis	-	111, 112
Brain		
Acute disseminated encephalomyelitis	ADEM	113
Pediatric autoimmune neuropsychiatric disorders associated with streptococcal infection	PANDAS	20, 21
Hashimoto's encephalitis	-	22
Rasmussen's encephalitis	RE	114, 115

3. THE SPECTRUM OF NEUROIMMUNOLOGIC DISORDERS

The clinical, immunologic and pathologic findings in TM patients place this disorder on a continuum of neuroimmunologic disorders (Table 1). In each, there is an acquired alteration in the innate or acquired immune system, resulting in dysfunction and/or cellular injury to cells within the nervous system. Many of the disorders may be post-infectious (TM, ADEM, GBS, PANDAS), suggesting that the infectious agent triggers breakdown of immune tolerance for self antigens. In GBS, a preceding infectious agent (often *Campylobacter jejuni*), may encode a molecular mimic that resembles a host ganglioside expressed on peripheral nerves, resulting in immune-mediated injury (13-15). In ADEM and TM, superantigen-mediated activation of T lymphocytes may be an important event in breaking down immune tolerance (16-19). In PANDAS, evidence to date suggests that the development of anti-neuronal antibodies following infection with Group A beta hemolytic streptococcus (GABHS) results in dysfunction of basal ganglia (20, 21). Similarly, NMO, recurrent TM, SPS, paraneoplastic encephalomyelitis, MG and Hashimoto's encephalopathy have prominent humoral derangements that may contribute to neural dysfunction (for reviews, see (19, 22-26). Other disorders in this group, such as polymyositis, TSP/HAM, Rasmussen's encephalopathy and TM have prominent T lymphocyte derangements (for review, see (27-29). MS has recently been shown to have multiple distinct pathologic subtypes with differing degrees of T lymphocyte, macrophage, antibody and complement contributions (9). In many of the other disorders as well, it is unlikely that a single immune system component is wholly responsible for the clinical disorder, and mixed dysfunction of T lymphocytes, B lymphocytes, macrophages/microglial cells and even NK cells may contribute. Similarly, the mechanisms of neural injury may involve multiple pathways including T lymphocyte killing of neural cells, cytokine injury, activation of toxic microglial pathways, immune-complex deposition, excitotoxic or apoptotic neural injury. Though TM exists on a continuum of neuroimmunologic disorders, the reasons to explain distinct focality of these disorders are unclear. Potential explanations include unique antigen representation within a focal area of the spinal cord, unique trafficking of immune effector cells within a particular region of the spinal cord, or regionally-specific differences in the immune response (for example, differential elaboration of cytokines or efficient antigen presentation to the immune system within the spinal cord).

4. HISTORY OF TM

Several cases of "acute myelitis" were described in 1882, and pathologic analysis revealed that some were due to vascular lesions and others to acute inflammation (30). Subsequently, the occurrence of >200 cases of postvaccinial encephalomyelitis was reported between 1922 and 1923 in England, a complication of smallpox and rabies vaccination (31). Pathologic analyses of fatal cases revealed inflammatory cells and demyelination rather than the vascular pathology noted in earlier reports. Subsequent reports emphasized that TM may be a post-infectious "allergic" response since in many patients, "the fever had fallen and the rash had begun to fade" when myelitis symptom began (32). Several cases were then reported over the next two

Table 2. TM Diagnostic Criteria

Inclusion criteria
1. Development of sensory, motor or autonomic dysfunction attributable to the spinal cord 2. Bilateral signs and/or symptoms 3. Clearly-defined sensory level 4. Inflammation within the spinal cord demonstrated by CSF pleocytosis *or* elevated IgG index *or* gadolinium enhancement (If none of the inflammatory criteria is met at symptom onset, repeat MRI and LP evaluation between 2-7 days following symptom onset)
Exclusion criteria
1. History of previous radiation to the spine within the past 10 years 2. Clear arterial distribution clinical deficit consistent with thrombosis of the anterior spinal artery 3. Extra-axial compressive etiology by neuroimaging (MRI of spine preferred. CT myelography acceptable. X-ray, CT of spine are not adequate) 4. Abnormal flow voids on the surface of the spinal cord c/w AVM 5. Serologic or clinical evidence of connective tissue disease (sarcoidosis, Behcet's disease, Sjogren's syndrome, SLE, mixed connective tissue disorder etc) (Diagnostic of Connective-Tissue Associated TM) 6. History of clinically apparent optic neuritis (Diagnostic of Neuromyelitis optica) 7. CNS manifestations of syphilis, Lyme disease, HIV, HTLV-1, mycoplasma, other viral infection (e.g. HSV-1, HSV-2, VZV, EBV, CMV, HHV-6, enteroviruses) (Diagnostic of Infectious myelitis) 8. Progression to nadir in less than 4 hours from symptom onset 9. Symptom progression continues beyond 21 days from symptom onset 10. Brain and spinal cord MRI abnormalities suggestive of MS and presence of oligoclonal bands in CSF (Suggestive of TM associated with MS. Apply McDonald criteria to definitively define MS)

AVM= arteriovenous malformation; SLE= systemic lupus erythematosus; HTLV-1= human T-cell lymphotropic virus-1; HSV= herpes simplex virus; VZV= varicella zoster virus; EBV=Epstein-Barr virus; CMV= cytomegalovirus; HHV= human herpes virus

decades in which infectious agents, including measles, rubella and mycoplasma, were directly isolated from spinal fluid of patients with TM, suggesting that direct infection of the spinal cord may be involved in some patients (33, 34). It was in 1948 that Dr. Suchett-Kaye, an English neurologist at St. Charles Hospital in London first utilized the term "acute transverse myelitis" (35) in reporting a case of rapidly progressive paraparesis with a thoracic sensory level, occurring as a post-infectious complication of pneumonia.

Acute transverse myelopathy (which includes non-inflammatory causes) and TM have often been used interchangeably throughout the published literature. One report established the following criteria for transverse myelopathy: bilateral spinal cord dysfunction developing over a period of < 4 weeks with a well-defined upper sensory level, no antecedent illness, and exclusion of compressive etiologies (10). Subsequently, these criteria were altered to include only those patients who developed motor, sensory, and sphincter dysfunction acutely over < 14 days, whereas patients with other neurologic disease or underlying systemic diseases were excluded (4). Other authors then defined TM as acutely developing paraparesis (no specification of a time to maximum deficit) with bilateral sensory findings and impaired sphincteric function, a spinal segmental level of sensory disturbance, a stable non-progressive course (to distinguish from progressive spastic paraparesis), and no clinical or laboratory evidence of spinal cord compression (2). Patients were excluded if they had progressive spastic paraparesis, a patchy sensory deficit or hemicord syndrome, syphilis, severe back trauma, metastatic cancer, or encephalitis. To further separate diseases with distinct etiologies, suggested criteria for TM were revised to include only those patients who progressed to maximum deficit within 4 weeks and to exclude other known diseases including arteriovenous malformations of the spinal cord, human T-cell lymphotropic virus-1 (HTLV-1) infection, and sarcoidosis (3). With use of these criteria, cases of TM were classified as parainfectious, related to MS, spinal cord ischemia, or idiopathic.

Most recently, acute noncompressive myelopathies were classified according to an etiologic scheme (36)-1) those related to MS, 2) systemic disease (e.g., systemic lupus erythematosus [SLE], anti-phospholipid syndrome, Sjögren disease), 3) postinfectious , 4) delayed radiation myelopathy, 5) spinal cord infarct, and 6) idiopathic myelopathy. The presence of MS or systemic disease was determined by standard criteria (37-39), whereas parainfectious myelopathies were diagnosed on the basis of positive IgM serology or a fourfold or greater increase in IgG levels on two successive tests to a specific candidate/infectious agent. Delayed radiation myelopathy was diagnosed according to clinical history, and spinal cord infarction was diagnosed on the basis of appropriate clinical and imaging findings in the absence of other likely etiologies. Idiopathic transverse myelopathy was defined in those individuals that could not be otherwise categorized and constituted 16.5% of this series.

5. DEFINITION OF TM

5.1. Criteria of TM

We recently proposed a set of diagnostic criteria which served to distinguish TM from non-inflammatory myelopathies and to distinguish idiopathic TM from TM associated with multifocal CNS and multi-systemic inflammatory disorders. These criteria are summarized in Table 2. A diagnosis of TM requires evidence of inflammation within the spinal cord. Because spinal cord biopsy is not a practical option in the routine evaluation of these patients, spinal MRI and CSF analysis are the only tools currently

available to determine the presence of inflammation within the involved lesion. Gadolinium enhanced spinal MRI and a lumbar puncture are mandatory in the evaluation of suspected TM, and we proposed that abnormal gadolinium enhancement of the spinal cord or CSF pleocytosis or elevated CSF IgG index be required for a diagnosis of TM (1). If none of the inflammatory criteria are met at symptom onset, MRI and lumbar puncture evaluation should be repeated between 2 and 7 days following symptom onset to determine if these inflammatory criteria are met. IgG synthesis rate is a less specific indicator of CNS inflammation than is CSF IgG index (40, 41), and should not be utilized in the diagnosis. Vascular myelopathies can be differentiated from TM by a progression of symptoms to maximal severity in less than 4 hours and the lack of inflammation as defined above. However, these criteria do not completely distinguish vascular myelopathies from TM, since myelopathies associated with venous infarcts or with vascular malformations may be more slowly progressive and may meet the other criteria for TM.

Differentiating idiopathic TM from TM attributed to an underlying disease is also important. Many systemic inflammatory disorders (e.g. sarcoidosis, SLE, Behçet's disease, Sjögren syndrome) may involve the nervous system and TM may be one the possible presentations. Therefore, all patients presenting with TM should be investigated for the presence of systemic inflammatory disease. Important historical information should be obtained from the patient regarding the presence of rashes, night-sweats, oral or genital ulcers, sicca symptoms, shortness of breath, pleuritic pain or hematuria. Examination should attempt to detect the presence of uveitis or retinitis, decreased lacrimation or salivation, skin rash (malar, livedo reticularis, erythema nodosum), oral or genital ulcers, adenopathy, pleuritic or pericardial friction rub, or organomegaly. Laboratory studies should include the following: CBC with differential and smear, ANA, SS-A, SS-B, ESR, and complement. Additional laboratory testing may be required if signs of a systemic vasculitis are detected.

From this evaluation, it may be possible to distinguish idiopathic TM from disease-associated TM (i.e., TM associated with multi-focal CNS disease or systemic inflammatory disease). This distinction is important since patients at high risk of developing MS may be evaluated more closely or may be offered immunomodulatory treatment (42). Similarly, patients with disease-associated TM may need to be closely followed for recurrent systemic and neurologic complications and should be offered immunosuppressive treatment to decrease the risk of recurrence. We routinely offer such patients treatment with azathioprine (2-2.5 mg/kg/d), methotrexate (15-20 mg/week), mycophenolate (2-2.5 g/d) or cyclophosphamide (pulse of 500-1000 mg/m^2 q 4-6 weeks for severe cases) although controlled trials of these interventions are lacking and currently needed.

5.2. Evaluation of patients with acute myelopathies

We recently proposed a diagnostic approach for evaluating patients with acute myelopathies (1). This algorithm is reproduced here as it has been applied to 354 consecutive patients seen at The Johns Hopkins Transverse Myelitis Center since July 1999 (Figure 1). The first priority is to rule out a compressive lesion. If a myelopathy is suspected based on history and physical exam, a gadolinium enhanced MRI of the spinal cord should be obtained as soon as possible. If there is no structural lesion such as epidural blood or a spinal mass, then the presence or absence of spinal cord inflammation should be documented with a lumbar puncture. The absence of pleocytosis would lead to consideration of non-inflammatory causes of myelopathy such as arteriovenous malformations, epidural lipomatosis, fibrocartilaginous embolism or possibly early inflammatory myelopathy (i.e. a false negative CSF). In the presence of an inflammatory process (defined by gadolinium enhancement, CSF WBC pleocytosis or elevated CSF immunoglobulin index), one should determine whether there is an infectious cause. Viral polymerase chain reaction assays should be performed to determine whether there is the presence of viral particles within the CNS (herpes simplex 1 and 2, varicella zoster, cytomegalovirus, Epstein Barr virus and enterovirus). Detection of lyme disease of the CNS typically is based on antibody detection methods (ELISA with confirmatory western blot) and the CSF/serum index is often helpful in determining whether there is true neuroborreliosis (43). Evidence of *M. pneumoniae* infection may be determined by seroconversion, which is defined by a 4-fold increase in titer or a single titer of ≥1:128.

The next priority is to define the regional distribution of demyelination within the CNS, since several disorders (i.e. multiple sclerosis or acute disseminated encephalomyelitis) may present with TM as the initial manifestation of disease or in the setting of multifocal disease. A gadolinium enhanced brain MRI and visual evoked potential should be ordered to look for these entities. The absence of multifocal areas of demyelination would suggest the diagnosis of isolated TM and lead to appropriate treatment measures (Section 8) (1).

TM is often misdiagnosed as acute inflammatory demyelinating polyradiculoneuropathy (AIDP) or Guillain-Barré syndrome (GBS), because both conditions may present with rapidly progressive sensory and motor loss involving principally the lower extremities. Table 3 illustrates key differential points between these two conditions. A pure paraplegia or paraparesis with a corresponding distribution of sensory loss may favor TM, while GBS may present with a gradient of motor and sensory loss involving the lower extremities greater than the upper extremities. When weakness and sensory loss involves both the upper and lower extremities equally with a distinct spinal cord level, then TM involving the cerival region is more likely. Pathologically brisk deep tendon reflexes are supportive of TM. However, patients with fulminant cases of TM that includes significant destruction of spinal cord gray matter may present with hypotonia and have decreased or absent deep tendon reflexes. Urinary urgency or retention is a common early finding in TM and is less common in GBS. In GBS, dysesthetic pain, involvement of the upper extremity and cranial nerve 7, and absent deep tendon reflexes involving the upper

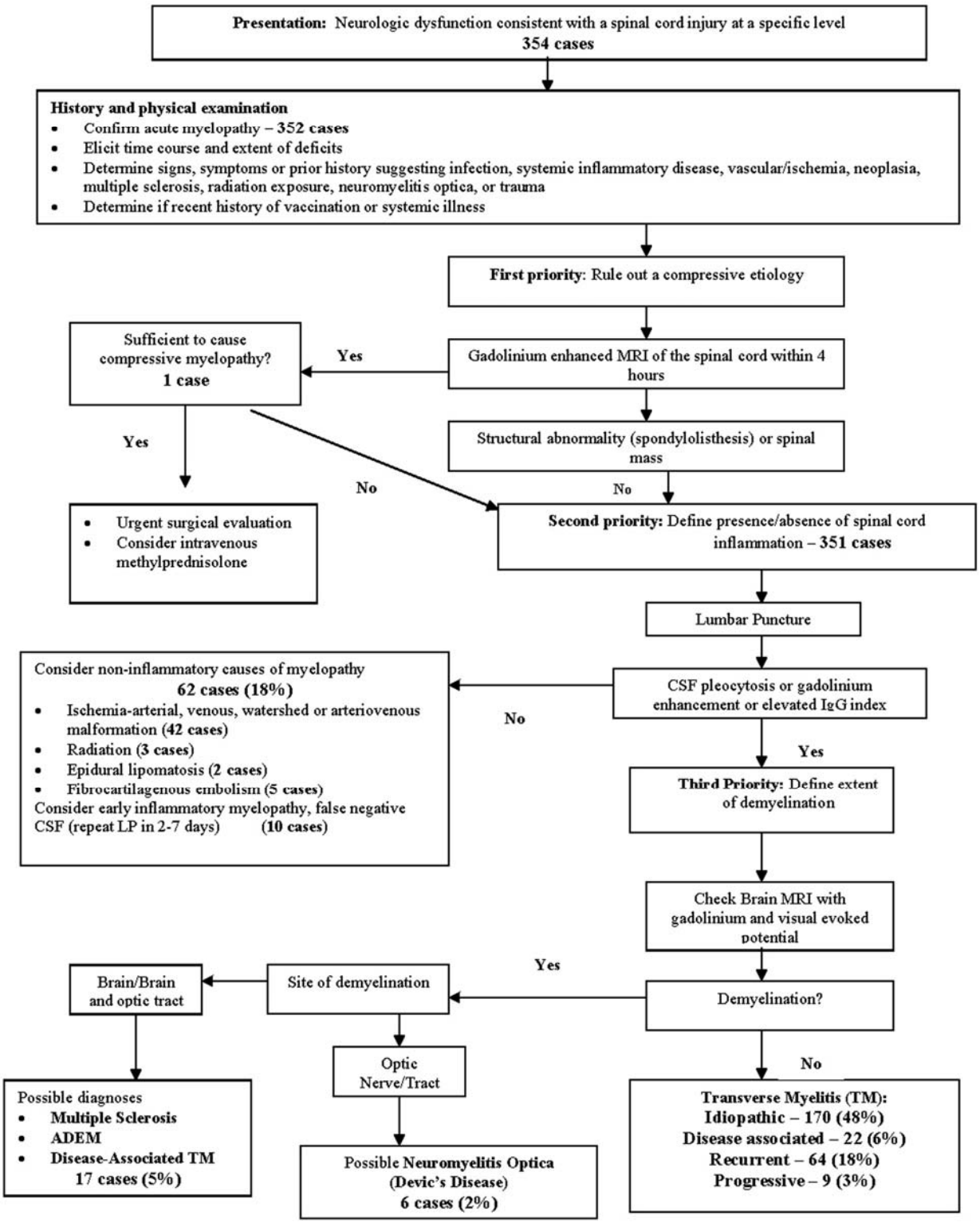

Figure 1. Diagnostic Approach to Acute Myelopathy (JHTMC case series)

extremities are more common findings. An MRI of the spinal cord may show an area of inflammation in TM but not in GBS. Although cerebral spinal fluid findings in TM are not consistent and an elevated cell count may be absent, there is usually a moderate lymphocytic pleocytosis and elevated protein level. This is in contrast to the albumino-cytologic dissociation of the CSF seen in GBS (44).

Table 3. Comparison of TM and GBS

Characteristics	TM	GBS	Distinguishing Feature
Motor findings	Paraparesis or quadriparesis	Ascending weakness LE>UE in the early stages	TM: if UE involvement, often as severe as LE; often no UE involvement GBS: There usually is UE involvement and it is less severe than LE involvement early in the disease
Sensory findings	Usually can diagnosis a spinal cord level	Ascending sensory loss LE>UE in the early stages	TM: sensory level usually identified. Often no arm involvement GBS: no sensory level, usually UE less affected than LE early in the disease
Autonomic findings	Early loss of bowel and bladder control	Autonomic dysfunction of the cardiovascular (CV) system	TM: urinary urgency or retention early and prominent; CV instability only in severe cases higher than T6. GBS: urinary urgency or retention less common; CV instability is more common
Cranial nerve findings	None	EOM palsies or facial weakness	GBS: cranial neuropathies are more common than in TM
Electrophysiologic findings	EMGNCV findings may be normal or may implicate the spinal cord: Prolonged central conduction on somatosensory evoked potential (SEP) latencies or missing SEP in conjunction with normal sensory nerve action potentials	EMG/NCV findings confined to the PNS: motor and/or sensory nerve conduction velocity reduced, distal latencies prolonged; conduction block; reduced H reflex usually present	The lack of peripheral nerve abnormalities in a patient with progressive weakness and sensory loss should suggest evaluation of the spinal cord for pathology Conversely, patients with suspected TM but equivocal clinical, lab or radiologic findings may warrant peripheral nerve examination
MRI findings	Usually a focal area of increased T2 signal with or without gadolinium enhancement	Normal	MRI abnormalities may be helpful in diagnosing a patient who is suspected of having GBS from TM
CSF	Usually, CSF pleocytosis and/or increased IgG index	Usually, elevated protein in the absence of CSF pleocytosis	CSF pleocytosis and elevated IgG index may be helpful in diagnosing a patient who is suspected of having GBS from TM

5.3. Differential Diagnoses/Non-inflammatory myelopathies

As indicated above, the suggested diagnostic algorithm and criteria first distinguish inflammatory from non-inflammatory myelopathies. If the history and evaluation do not suggest a systemic or a CNS inflammatory process, then consideration should be given to ischemic, metabolic, or structural causes of myelopathy. Vascular myelopathy may be fairly easy to recognize in the setting of an anterior spinal artery infarct (sudden onset of symptoms with relative preservation of posterior column function). Or it may be more difficult to recognize in the setting of a venous infarct or in the setting of a vascular malformation. Venous infarct may be suspected when a clinical history and serologic studies are suggestive of a pro-thrombotic state (deep venous thrombosis, pulmonary embolus, livedo reticularis, anti-phospholipid antibodies, factor V Leiden mutation, APC resistance or prothrombin gene mutation). A vascular malformation (dural AV fistula, AVM, cavernous angioma) may be suspected if the imaging suggests the presence of flow voids or bleeding into the spinal cord. A dural AV fistula is most likely to occur in men older than 40 years old and may present with a "stuttering" or progressive myelopathy. Patients with a dural AV fistula may report a postural dependence of symptoms and pain is usually a prominent feature. Spinal angiography is the diagnostic study of choice to define the presence of a vascular malformation. Surgical or endovascular treatment may result in stabilization or clinical improvement in a substantial proportion of patients (45-47).

Fibrocartilagenous embolism is a rare (though likely underreported) cause of acute myelopathy (48-51). In most reported cases, there has been a sudden increase in intrathoracic or intraabdominal pressure prior to the onset of symptoms, and in several autopsies, fibrocartilageneous material was found to have embolized to the spinal cord. The most likely explanation for these findings is that the nucleus pulposis herniated vertically into the vertebral body sinusoids in response to markedly elevated pressure, followed by further herniation through vascular channels into the spinal cord parenchyma. Fibrocartilagenous embolism should be suspected in a patient with a sudden onset of myelopathy that reaches its maximal severity within hours in a patient with an antecedent elevation of intra-abdominal or intrathoracic pressure. Imaging may show acute loss of intervertebral disk height and vertebral body end-plate changes adjacent to an area of T2 signal abnormality within the spinal cord.

Radiation myelopathy may develop at any time up to 15 years following ionizing radiation. Pathologic studies

show preferential involvement of myelinated tissue and blood vessels and it is likely that cellular death of oligodendrocytes and endothelial cells contributes to the clinical disorder (52). Patients may present with slowly progressive spasticity, weakness, hyperreflexia and urinary urgency. There is often a corresponding T2 signal abnormality that is non-enhancing and preferentially affects the more superficial spinal cord white matter. Though anticoagulation (53, 54) or hyperbaric oxygen (55-57) have been proposed as treatment options, neither has been clearly shown to be effective in patients with radiation myelopathy.

5.4. Discrimination from Multiple Sclerosis

TM can be the presenting feature of MS. Patients who are ultimately diagnosed with MS are more likely to have asymmetric clinical findings, predominant sensory symptoms with relative sparing of motor systems, MR lesions extending over fewer than two spinal segments, abnormal brain MRI, and oligoclonal bands in the CSF (36, 58-62). A patient with monofocal CNS demyelination (Transverse Myelitis or optic neuritis) whose brain MRI shows lesions consistent with demyelination (63) has an 83% chance of meeting clinical criteria for MS over the subsequent decade compared with 11% of such patients with normal brain MRI (64).

6. NATURAL HISTORY OF TM

6.1. Epidemiology and Clinical Presentation of TM

TM affects individuals of all ages with bimodal peaks between the ages of 10 and 19 years and 30 and 39 years (2-5). There are approximately 1400 new cases diagnosed in the United States per year and approximately 34,000 people have chronic morbidity from TM at any given time. Approximately 28% of reported TM cases are in children [JHTMC case series]. There is no sex or familial predisposition to TM.

A preceding illness including nonspecific symptoms such as fever, nausea, and muscle pain has been reported in about 40% of pediatric cases within 3 weeks of the onset of the disorder (44, 65)[JHTMC case series]. 30% of all cases of pediatric TM cases referred to an academic center had a history of an immunization with one month of the onset of symptoms [JHTMC case series]. Although a history of an immunization preceding the onset of TM is commonly reported, the relationship to this condition is unclear because of insufficient information.

TM is characterized clinically by acutely or subacutely developing symptoms and signs of neurological dysfunction in motor, sensory and autonomic nerves and nerve tracts of the spinal cord. Weakness is described as a rapidly progressive paraparesis starting with the legs and occasionally progresses to involve the arms as well. Flaccidity maybe noted initially with gradually appearing pyramidal signs by the second week of the illness. A sensory level can be documented in most cases. The most common sensory level in adults is the mid-thoracic region, though children may have a higher frequency of cervical spinal cord involvement and a cervical sensory level (66). Pain may occur in the back, extremities, or abdomen. Paresthesias are a common initial symptom in adults with TM but are unusual for children (67). Autonomic symptoms consist variably of increased urinary urgency, bowel or bladder incontinence, difficulty or inability to void, incomplete evacuation or bowel constipation (8). Also commonly the result of sensory and autonomic nervous system involvement in TM is sexual dysfunction (68 , 69). Genital anesthesia from pudendal nerve involvement (S2-S4) results in impaired sensation in men and women. Additional male sexual problems with parasympathetic (S2-S4) and sympathetic (T10-L2) dysfunction in TM patients include erectile dysfunction, ejaculatory disorders and difficulty reaching orgasm. Corresponding female sexual problems include reduced lubrication and difficulty reaching orgasm.

In addition to the signs and symptoms of direct spinal cord involvement by the immune system in TM, there also appears to be indirect effects manifested as depression that are reminiscent of what has been described in MS (unpublished observations) (70). This depression does not correlate significantly with the degree of physical disability, and can have lethal consequences resulting in suicide in severe cases if left untreated.

When the maximal level of deficit is reached, approximately 50% of patients have lost all movements of their legs, virtually all patients have some degree of bladder dysfunction, and 80-94% of patients have numbness, paresthesias or band like dysesthesias (2-7). In more than 80%, patients reach their clinical nadir within 10 days of the onset of symptoms (44). Although the temporal course may vary, neurologic function usually progressively worsens during the acute phase from between 4-21 days (1).

A spinal MRI and lumbar puncture often show evidence of acute inflammation (2-4, 7, 10, 61, 71). In our case series of 170 idiopathic TM cases, spinal MRI showed a cervical T2 signal abnormality in 44% and a thoracic T2 signal abnormality in 37% of cases. 5% of patients had multifocal lesions and 6% showed a T1 hypointense lesion. This corresponded to the following clinical sensory levels: 22% cervical, 63% thoracic, 9% lumbar, 6% sacral and no sensory level in 7%. The rostral-caudal extent of the lesion ranged from one vertebral segment in many to spanning the entire spinal cord in two patients. In 74% of patients, the T2 lesion also enhanced with gadolinium. 42% of patients had a CSF pleocytosis with a mean WBC count of 38±13 cells (range 0-950 cells). 50% of the patients revealed an elevated protein level (mean protein level 75±14 g/dl). Table 4 lists some of the radiologic features that distinguish various acute myelopathies.

6.2. Monophasic vs. Recurrent TM

75-90% of TM patients experience monophasic disease and have no evidence of multi-systemic or multiphasic disease. Most commonly, symptoms will stop progressing after 2-3 weeks and spinal fluid and MRI abnormalities will stabilize and then begin to resolve. There are several features, however, that predict recurrent disease (Table 5). Patients with multifocal lesions within the spinal

Table 4. Imaging Features of Acute Myelopathies

Imaging feature	Suggested diagnosis
Blood within the spinal cord (bright and dark T1 and T2 signal)	Vascular malformation such as cavernous angioma or dural AV fistula
Flow voids within spinal cord	Dural AV fistula or AVM
Central T2 signal abnormality	Venous hypertension
Ring-enhancing lesion	Infection or tumor (but consider course of IV steroids to rule out inflammatory process before progressing to biopsy)
Acute loss of vertical intervertebral disc height and corresponding T2 signal abnormality	Consider fibrocartilagenous embolism
Fusiform lesion extending over >3 sc segments	Consider Neuromyelitis optica or disease-associated TM
T2 bright lesion in white matter occupying less than 2 spinal cord segments in rostral-caudal extent and less than 50% of the cord diameter	Consider MS
T2 spinal cord lesion adjacent to disk herniation or spondylitic ridge, but lack of spinal cord compression	Consider dynamic spinal cord compression only during flexion or extension (flexion-extension x ray to determine the presence of abnormal spinal column mobility; MRI in flexion or extended position instead of in neutral position)

Table 5. Recurrent Vs. Monophasic TM

Characteristics	Monophasic	Recurrent
Spinal MRI	Single T2 lesion	Multiple distinct lesions or fusiform lesion extending over ≥ 3 spinal cord segments
Brain MRI	Normal	T2/FLAIR abnormalities
Blood Serology	Normal	≥ 1 autoantibodies (ANA, dsDNA, phospholipid, c-ANCA)
SS-A	Negative	Positive
CSF Oligoclonal Bands	Negative	Postive
Systemic disease	None	Connective tissue disorder
Optic Nerve Involvement	No	Yes
CSF IL-6	Sustained elevation (>50 pg/ml) (research only)	Declining or normal (<50 pg/ml) (research only)

cord, demyelinating lesions in the brain, oligoclonal bands in the spinal fluid, mixed connective tissue disorder, or serum autoantibodies (most notably SS-A) are at a greater risk of recurrence (72). Preliminary studies suggest that patients who have persistently abnormal CSF cytokine profiles (notably IL-6) may also be at increased risk for recurrent TM, though these findings must be validated before they are utilized clinically (73). At the current time, we do not understand the relative contribution of these factors to gauge whether chronic immunomodulatory treatment is warranted in high-risk patients.

6.3. Prognosis

Some patients with TM may experience recovery in neurologic function regardless of whether specific therapy was instituted. Recovery, if it occurs, should begin within 6 months and the vast majority of patients show some restoration of neurologic function within 8 weeks (67, JHTMC case series). Recovery may be rapid during months 3-6 after symptom onset and may continue, albeit at a slower rate, for up to 2 years (44, 66, JHTMC case series). Longitudinal case series of TM reveal that approximately 1/3 of patients recover with little to no sequelae, 1/3 are left with moderate degree of permanent disability, and 1/3 have severe disabilities (4, 5, 10, 44, 65). Knebusch estimated that a good outcome with normal gait, mild urinary symptoms, and minimal sensory and upper motor neuron signs occurred in 44%. A fair outcome with mild spasticity but independent ambulation, urgency and/or constipation, and some sensory signs occurred in 33%, and a poor outcome with the inability to walk or severe gait disturbance, absence of sphincter control and sensory deficit 23%. The patient cohort we follow at Johns Hopkins is more severe with only 20% experiencing a good outcome by those definitions, likely a reflection of referral bias to a tertiary care center. Symptoms associated with poor outcome include back pain as an initial complaint, rapid progression to maximal symptoms within hours of onset, spinal shock, and sensory disturbance up to the cervical level (67). The presence of 14-3-3 protein, a marker of neuronal injury, in the CSF during the acute phase may also predict a poor outcome (74).

7. IMMUNOPATHOGENESIS OF TM

7.1. General Pathology of TM

The pathology of acute myelopathies reflects the heterogeneous nature of thee disorders. Few studies to date have described the pathology of acute myelitis and the majority of these pathological descriptions are clinicopathological case reports (75-77). Pathological data from autopsies and biopsies from patients with suspected spinal cord lesions later confirmed to be associated with myelitis have been studied at the JHTMC {unpublished data). These data further confirm that TM is an inflammatory condition associated with immune-mediated

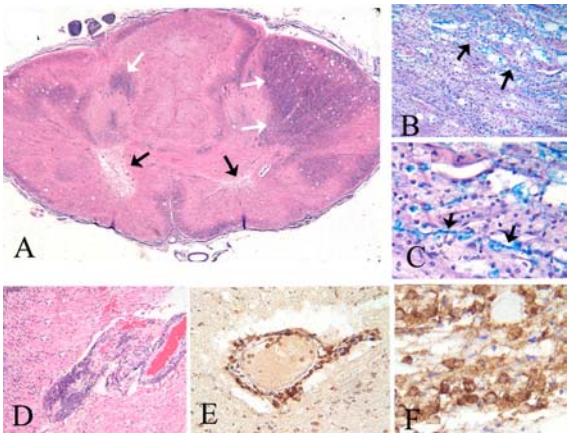

Figure 2. Histology of TM. A: Myelin staining of cervical spinal cord section from a patient who died during a subacute stage of TM. There are a few myelinated areas left (white arrows) and foci of cystic degeneration in the anterior horns (black arrows). The remaining of the spinal cord shows chronic inflammation and demyelination (LFB/HE stain). B: An area of demyelination from the same spinal cord as A that shows areas of active myelin and fiber degeneration (LFB/HE stain). C: High magnification view of few myelinated fibers left in areas of active inflammation (LFB/HE stain). D: Focal area of acute inflammation and perivascular accumulation of inflammatory cells seen in a biopsy obtained from a patient with acute TM (H&E stain). E: Perivascular infiltration by T lymphocytes as demonstrated by immunocytochemistry in an area of active inflammation in a patient with TM (CD3 immunostaining). F: Infiltration by macrophages in an area of myelitis (HLA-Dr immunostaining).

mechanisms. Indeed, all patients who met criteria for the diagnosis of TM and had tissue sampling of the spinal cord (biopsy or autopsy) had inflammatory changes. These pathologic abnormalities invariably included focal infiltration by monocytes and lymphocytes into segments of the spinal cord and perivascular spaces and an invariable astroglial and microglial activation (Figure 2). The magnitude and extension of these inflammatory features vary and are determined by the etiological factors and the temporal profile of the myelopathic changes. The presence of white matter changes, demyelination and axonal injury is prominent in postinfectious myelitis. However, involvement of the central compartment of the cord, gray matter or neurons is also prominent in some cases, a finding that supports the view that in TM, both gray and white matter compartments may be equally affected. In some biopsies obtained during the acute phases of myelitis, infiltration of CD4+ and CD8+ lymphocytes along with an increased presence of monocytes is quite prominent. In biopsies obtained during subacute phases of myelopathic lesions, prominent monocyte and phagocytic-macrophage infiltration is observed. In some cases, autoimmune disorders such as SLE, lead to vasculitic lesions that produce focal areas of spinal cord ischemia without prominent inflammation (78). These immunopathological observations further confirm that TM is an immune-mediated disorder that involves cellular reactions and perhaps humoral factors that injure compartments of the spinal cord.

7.2. Immunopathogenesis of TM

The pathogenesis of TM is believed to be immune-mediated. In support of this mechanism, most patients have CSF pleocytosis and blood-brain barrier breakdown within a focal area of the spinal cord. In 30-60% of idiopathic TM cases, there is an antecedent respiratory, gastrointestinal or systemic illness (2-5, 7, 10, 65).

Therefore, in TM patients, it is likely that there is abnormal activation of the immune system resulting in inflammation and injury within the spinal cord. Several potential mechanisms for this have been proposed (19). A variety of infectious agents encode molecular mimics (e.g. proteins, glycolipids or proteoglycans) that resemble self antigens. Generation of an immune response to the mimic then may result in cross-reactive immune activation against self tissue. This mechanism is well established in Guillain-Barré syndrome, a monophasic, usually post-infectious inflammatory disorder of peripheral nerves (79-81). More recent studies have implicated this mechanism in a variety of CNS inflammatory diseases as well (82-85). The molecular mimic may stimulate T lymphocytes, thus breaking down the immune tolerance of self tissue that had previously existed (82). Alternatively, the molecular mimic may stimulate the generation of antibodies which cross react with self antigens, resulting in immune complex formation and activation of complement-mediated or cell-mediated injury to self tissue (83-85). These autoantibodies may function as an agonist to cellular receptors, altering cellular signaling, metabolism or activity (85).

Another link between an antecedent infection and the development of TM may be the fulminant activation of lymphocytes by microbial superantigens. Superantigens are microbial peptides that have a unique capacity to stimulate a large number of lymphocytes in a unique manner compared with conventional antigens. The stimulation of large numbers of lymphocytes may trigger autoimmune disease by activating autoreactive T cell clones (86, 87). Whereas very little is known definitively about the inciting cause of inflammation in the CNS of patients with TM, nothing is currently understood about the mechanisms of tissue injury in this inflammatory disease.

We recently have carried out a series of investigations that describe immune derangements in TM patients (73, 88). We have found that interleukin 6 (IL-6) levels in the spinal fluid of TM patients were markedly elevated compared to control patients and to MS patients. While relatively low levels of IL6 in MS patients did not correlate with disability, IL6 levels in TM patients strongly correlated with and were highly predictive of disability. IL-6 levels in TM patient's CSF correlated with Nitric Oxide (NO) metabolites, which also correlated with disability. We suggest, therefore, that marked upregulation of IL6 correlates with increased NO production and that this

elevation is etiologically related to tissue injury leading to clinical disability in TM.

8. TREATMENT OF TM

8.1. Intravenous Steroids

Intravenous steroid is often instituted for patients with acute TM. Though there is no randomized, placebo-controlled study that supports this approach, evidence from related disorders and clinical experience support this treatment (89-93). Additionally, there are several small studies which support the administration in patients with TM (94-97). A study of five children with severe TM who received Solumedrol (1g/1.73 meter squared per day) for 3 or 5 consecutive days followed by oral prednisone for 14 days reported beneficial effects compared to ten historic controls (96). In the steroid treated group, the median time to walking was 23 days vs. 97 days, full recovery occurred in 80% vs. 10%, and full motor recovery at 1 year was present in 100% vs. 20%. No serious adverse effects from the steroid treatments occurred.

Other investigations have suggested that intravenous steroid administration may not be effective in TM patients (44, 67, 98). The most significant of these manuscripts (98) compared 12 TM patients seen between 1992-1994 who did not get steroids with 9 patients seen between 1995-1997 who did. Although the authors claimed that there was no statistically significant difference in the outcomes between the groups, it is evident that the TM patients who received steroids were more likely to recover and fewer had a poor outcome on the Barthel Index (33% vs. 67%). Therefore, the available evidence suggests that intravenous steroids are somewhat effective if given in the acute phase of TM. However, these studies did not rigorously define TM and therefore likely included patients with non-inflammatory myelopathies.

At our center, we routinely offer intravenous methylprednisolone (1000 mg) or dexamethasone (200 mg) for 3-5 days unless there are compelling reasons to avoid this therapy. The decision to offer continued steroids or add a new treatment is often based on the clinical course and MRI appearance at the end of 5 days of steroids.

8.2. Plasma Exchange

Plasma exchange (PLEX) is often initiated if a patient has moderate to severe TM (i.e. inability to walk, markedly impaired autonomic function and sensory loss in the lower extremities) and exhibits little clinical improvement within 5-7 days of intravenous steroids. PLEX has been shown to be effective in adults with TM and other inflammatory disorders of the CNS (99-101). Predictors of good response to PLEX include early treatment (less than 20 days from symptom onset), male sex, and a clinically incomplete lesion (i.e. some motor function in the lower extremities, intact or brisk reflexes) (102). It is our experience that PLEX may significantly improve outcomes of patients with severe (though incomplete) TM and who have not significantly improved on intravenous steroids.

8.3. Other Immunomodulatory Treatment

No controlled information currently exists regarding the use of other treatment strategies in patients with acute TM. Some clinicians consider pulse dose intravenous cyclophosphamide (500-1000 mg/m2) for patients with TM that continues to progress despite intravenous steroid therapy. It is the experience at our center that some patients will respond significantly to intravenous cyclophosphamide and this treatment is worthy of consideration while we await double blinded placebo trials. However, cyclophosphamide should be administered under the auspices of an experienced oncology team, and caregivers should monitor the patient carefully for hemorrhagic cystitis and cytopenias.

CSF filtration is a new therapy, not yet available in the United States, in which spinal fluid is filtered for inflammatory factors (including cells, complement, cytokines and antibodies) prior to being reinfused into the patient. In a randomized trial of CSF filtration vs. PLEX for AIDP, CSF filtration was better tolerated and was at least as effective (103). Clinical trials for CSF filtration are currently being initiated.

Chronic immunomodulatory therapy should be considered for the small subgroup of patients with recurrent TM. Although the ideal treatment regimen is not known, we consider a two year course of oral immunomodulatory treatment in patients with two or more distinct episodes of TM. We most commonly treat patients with azathioprine (150-200 mg/d), methotrexate (15-20 mg/week) or mycophenolate (2-3 gm/day), though oral cyclophosphamide (2 g/kg/day) may also be used in patients with systemic inflammatory disease. On any of these medicines, patients must be followed for transaminitis or leukopenias.

8.4. Long Term Management

Many patients withTM will require rehabilitative care to prevent secondary complications of immobility and to improve their functional skills. It is important to begin occupational and physical therapies early during the course of recovery to prevent the inactivity related problems of skin breakdown and soft tissue contractures that lead to loss of range of motion. The principles of rehabilitation in the early and chronic phases after TM are summarized in Tables 6 and 7. During the early recovery period, family education is essential to develop a strategic plan for dealing with the challenges to independence following return to the community. Assessment and fitting for splints designed to passively maintain an optimal position for limbs that cannot be actively moved is an important part of the management at this stage.

The long term management of TM requires attention to a number of issues. These are the residual effects of any spinal cord injury including TM. In addition to chronic medical problems, there are the ongoing issues

Table 6. Chronic Management of Patients with TM

General	• Rehabilitation is critical • Strongly consider inpatient rehabilitation • Daily land based and/or water based therapy for 8-12 weeks • Daily weight bearing for 45-90 minutes. Standing frame if non-ambulatory • bone densitometry: Vitamin D, Calcium • Look for depression and treat if interfering with rehabilitation
Bladder dysfunction	• Assess ability to void spontaneously • Avoid Crede (bearing down to initiate urination) since may be dangerous • Check post void residual. If >80cc, consider clean intermittent catheterization (goal less than 400 cc volumes) • Cystometrogram not required in acute phase • Anticholinergic Rx if sig. urgency • Cranberry juice for urine acidification
Bowel dysfunction	• high fiber diet • increased fluid intake • digital disimpaction • bowel program: colace, senokot, dulcolax, docusate PR, bisacodyl in a water base, miralax, enemas PRN
Weakness	• strengthening program for weaker muscles • Passive and active ROM • PT/OT consultation • Splinting or orthoses when necessary
Pain or dysesthesias	• ROM exercises • gabapentin • carbamazepine • nortriptyline • tramadol • avoid narcotics if possible
Spasticity	• ROM exercises • aquatherapy • baclofen • tizanidine • diazepam • botulinum toxin • tiagabine

Early Rehabilitation Principles (weeks to months)

Table 7. Chronic Management of Patients with TM

General	• Avoid secondary complications • Examine for scoliosis in patients with high/severe lesions. • Serial flexion/extension x-ray of back to follow angle • Skin hygiene to avoid breakdown • Treat fatigue: Amantidine, Methylphenidate, Modafinil, CoQ10 • Bone densitometry: Vitamin D, Calcium, Bisphosphanate therapy • Consider and treat depression
Bladder dysfunction	• Urodynamics study for irritative or obstructive symptoms • Anticholinergic drug if detrusor hyperactive: extended release Ditropan or Detrol • Adrenergic blocker if sphicter dysfunction: Flomax, etc • Clean intermittent catherterization is safe for long term • Cranberry juice/Vitamin C for urine acidifcation • Consider sacral nerve stimulation
Bowel dysfunction	• high fiber diet • increased fluid intake • digital disimpaction • bowel med program: colace, senokot, dulcolax, docusate PR, bisacodyl in a water base, miralax, enemas PRN
Sexual dysfunction	• Phosphodiesterase V inhibitors
Weakness	• Strengthening program for weaker muscles • Passive and active ROM • Splinting or orthoses when necessary • Continued land-based and water based therapy • Ambulation devices when appropriate • Daily weightbearing for 45 –90 minutes. Standing frame if non-ambulatory • Orthopedics evaluation if joint imbalance
Pain or dysesthesias	• ROM exercises • gabapentin • carbamazepine • nortriptyline • tramadol • topical lidocaine (patch or cream) • intrathecal baclofen or opioids
Spasticity	• ROM exercises • aquatherapy • baclofen • tizanidine • diazepam • botulinum toxin • tiagabine • intrathecal baclofen trial

Late Rehabilitation Principles (months to years)

of ordering the appropriate equipment, re-entry into the school for children and community, and coping with the psychological effects of this condition by the patients and their families.

Spasticity is often a very difficult problem to manage. The key goal is to stay flexible with a stretching routine using exercises for active stretching and a bracing program with splints for a prolonged stretch. These splints are commonly used at the ankles, wrists, or elbows. An appropriate strengthening program for the weaker of the spastic muscle acting on a joint and an aerobic conditioning regimen are also recommended. These interventions are supported by adjunctive measures that include anti-spasticity drugs (e.g. diazepam, baclofen, dantrolene, tiagabine), therapeutic botulinum toxin injections, and serial casting. The therapeutic goal is to improve the function of the patient in performing specific activities of daily living (i.e. feeding, dressing, bathing, hygiene, mobility) through improving the available joint range of motion, teaching effective compensatory strategies, and relieving pain.

Another major area of concern is effective management of bowel and bladder function. A high fiber diet, adequate and timely fluid intake, medications to regulate bowel evacuations, and a clean intermittent urinary catheterization are the basic components to success. Regular evaluations by medical specialists for urodynamic studies and adjustment of the bowel program are recommended to prevent potentially serious complications.

9. SPECULATIONS ON FUTURE TREATMENTS OF TM

Work over the last few years has begun to reveal fundamental immune abnormalities in patients with TM and related neuroimmunologic disorders. The generation of autoantibodies and the presence of abnormally elevated cytokine levels in the spinal fluid are likely to be important immunopathogenic events in many patients with TM. Though TM is a heterogeneous syndrome that is associated with distinct pathologies, recent classification strategies have attempted to identify patients with likely similar immunopathogenic events. While current therapies are largely non-specific, future therapies will be more specifically targeted to those critical immunopathogenic events in TM. For example, evolving strategies will more effectively identify autoantibodies and the antigen to which they respond (104, 105), making it possible to develop specific targets to block the effects of these autoantibodies. Additionally, several strategies exist and more are currently being developed that specifically alter cytokine profiles or the effects of these cytokines within the nervous system. However, a cautionary note exists from recent studies examining TNF- α modulation in patients with multiple sclerosis or systemic rheumatologic disease: paradoxical demyelination may be triggered by TNF-α reduction in the blood (106). These findings may suggest that secondary alterations in immune system function may occur in response to blockade of any single pathway and that a “cocktail approach” aimed at halting multiple pro-inflammatory pathways may be ideal.

10. CONCLUSIONS

TM is a clinical syndrome caused by focal inflammation of the spinal cord. Many cases are post-infectious and are thought to be due to a transient abnormality in the immune system that results in injury to a focal area of the spinal cord. Recent studies have emphasized the need to classify TM according to whether there is evidence of systemic disease or multi-focal CNS disease. The importance of this may be that distinct treatment strategies are offered to patients with distinct forms of TM. Though the causes of TM remain unknown, recent advances have suggested specific cytokine derangements that likely contribute to sustained disability. Patients are often left with sustained disability due to injury of motor, sensory or autonomic neurons within the spinal cord. Future research will attempt to define triggers for the immune system derangements, effector mechanisms that propagate the abnormal immune response and cellular injury pathways initiated by the inflammatory response within the spinal cord. Ultimately, this may allow us to identify patients at risk for developing TM, specifically treat the injurious aspects of the immune response, and/or offer neuroprotective treatments which minimize the neural injury that occurs in response to the inflammation.

11. ACKNOWLEDGEMENTS

We acknowledge the support and efforts of the Transverse Myelitis Association (TMA) and its president Sanford Siegel. The TMA serves a critical role to the TM community and to researchers striving to understand and treat this disorder. We also acknowledge financial support of Bruce Downey, Katie Sandler Fund for TM research and the Claddagh Foundation to the Johns Hopkins TM Center.

12. REFERENCES

1. Transverse Myelitis Consortium Working Group: Proposed diagnostic criteria and nosology of acute transverse myelitis. *Neurology* 59, 499-505 (2002)

2. Berman, M. Feldman, S. Alter, M. Zilber, N. & E. Kahana: Acute transverse myelitis: incidence and etiologic considerations. *Neurology* 31, 966-971 (1981)

3. Jeffery, D.R. Mandler, R.N. & L.E. Davis: Transverse myelitis. Retrospective analysis of 33 cases, with differentiation of cases associated with multiple sclerosis and parainfectious events. *Arch Neurol* 50, 532-535 (1993)

4. Christensen, P.B. Wermuth, L. Hinge, H.H. & K. Bomers: Clinical course and long-term prognosis of acute

transverse myelopathy. *Acta Neurol Scand* 81, 431-435 (1990)

5. P.H. Altrocchi: Acute Transverse Myelopathy. *Arch Neurol* 9, 21-29 (1963)

6. Misra, U.K. Kalita, J. & S. Kumar: A clinical, MRI and neurophysiological study of acute transverse myelitis. *J Neurol Sci* 138, 150-156 (1996)

7. Lipton, H.L. & R.D. Teasdall: Acute transverse myelopathy in adults. A follow-up study. *Arch Neurol* 28, 252-257 (1973)

8. Sakakibara, R. Hattori, T. Yasuda, K. & T. Yamanishi: Micturition disturbance in acute transverse myelitis. *Spinal Cord* 34, 481-485 (1996)

9. Lucchinetti, C.F. Brueck, W. Rodriguez, M. & H. Lassmann: Multiple sclerosis: lessons from neuropathology. *Semin Neurol* 18, 337-349 (1998)

10. Ropper, A.H. & D.C. Poskanzer: The prognosis of acute and subacute transverse myelopathy based on early signs and symptoms. *Ann Neurol* 4, 51-59 (1978)

11. Tippett, D.S. Fishman, P.S. & H.S. Panitch: Relapsing transverse myelitis. *Neurology* 41, 703-706 (1991)

12. Pandit, L. & S. Rao: Recurrent myelitis. *J Neurol Neurosurg Psychiatry* 60, 336-338 (1996)

13. Oomes, P.G. Jacobs, B.C. Hazenberg, M.P. Banffer, J.R. & F.G. Van der Meche: Anti-GM1 IgG antibodies and Campylobacter bacteria in Guillain-Barre syndrome: evidence of molecular mimicry. *Ann Neurol* 38, 170-175 (1995)

14. Jacobs, B.C. Hazenberg, M.P. Van Doorn, P.A. Endtz, H.P. & F.G. Van der Meche: Cross-reactive antibodies against gangliosides and Campylobacter jejuni lipopolysaccharides in patients with Guillain-Barre or Miller Fisher syndrome. *J Infect Dis* 175, 729-733 (1997)

15. Nachamkin, I. Ung, H. Moran, A.P. Yoo, D. Prendergast, M.M. Nicholson, M.A. Sheikh, K. Ho, T. Asbury, A.K. McKhann, G.M. & J.W. Griffin: Ganglioside GM1 mimicry in Campylobacter strains from sporadic infections in the United States. *J Infect Dis* 179, 1183-1189 (1999)

16. Jorens, P.G. VanderBorght, A. Ceulemans, B. Van Bever, H.P. Bossaert, L.L. Ieven, M. Goossens, H. Parizel, P.M. Van Dijk, H. Raus, J. & P. Stinissen: Encephalomyelitis-associated antimyelin autoreactivity induced by streptococcal exotoxins. *Neurology* 54, 1433-1441 (2000)

17. Kornhuber, M.E. Ganz, C. Lang, R. Brill, T. & W. Schmahl: Focal encephalitis in the Lewis rat induced by intracerebral enterotoxin superantigen and amplified by activated intravenous splenocytes. *Neurosci Lett* 324, 93-96 (2002)

18. Eugster, H.P. Frei, K. Winkler, F. Koedel, U. Pfister, W. Lassmann, H. & A. Fontana: Superantigen overcomes resistance of IL-6-deficient mice towards MOG- induced EAE by a TNFR1 controlled pathway. *Eur J Immunol* 31, 2302-2312 (2001)

19. Kerr, D.A. & H. Ayetey: Immunopathogenesis of acute transverse myelitis. *Curr Opin Neurol* 15, 339-347 (2002)

20. Husby, G. van, d.R., I Zabriskie, J.B. Abdin, Z.H. & R.C. Williams Jr: Antibodies reacting with cytoplasm of subthalamic and caudate nuclei neurons in chorea and acute rheumatic fever. *J Exp Med* 144, 1094-1110 (1976)

21. Church, A.J. Cardoso, F. Dale, R.C. Lees, A.J. Thompson, E.J. & G. Giovannoni: Anti-basal ganglia antibodies in acute and persistent Sydenham's chorea. *Neurology* 59, 227-231 (2002)

22. Chong, J.Y. Rowland, L.P. & R.D. Utiger: Hashimoto encephalopathy: syndrome or myth? *Arch Neurol* 60, 164-171 (2003)

23. E.J. Dropcho: Remote neurologic manifestations of cancer. *Neurol Clin* 20, 85-122, vi (2002)

24. Vianello, M. Tavolato, B. & B. Giometto: Glutamic acid decarboxylase autoantibodies and neurological disorders. *Neurol Sci* 23, 145-151 (2002)

25. J. Lindstrom: Autoimmune diseases involving nicotinic receptors. *J Neurobiol* 53, 656-665 (2002)

26. Lucchinetti, C.F. Mandler, R.N. McGavern, D. Bruck, W. Gleich, G. Ransohoff, R.M. Trebst, C. Weinshenker, B. Wingerchuk, D. Parisi, J.E. & H. Lassmann: A role for humoral mechanisms in the pathogenesis of Devic's neuromyelitis optica. *Brain* 125, 1450-1461 (2002)

27. Pignone, A. Fiori, G. Del Rosso, A. Generini, S. & M. Matucci-Cerinic: The pathogenesis of inflammatory muscle diseases: on the cutting edge among the environment, the genetic background, the immune response and the dysregulation of apoptosis. *Autoimmun Rev* 1, 226-232 (2002)

28. Nagai, M. & M. Osame: Human T-cell lymphotropic virus type I and neurological diseases. *J Neurovirol* 9, 228-235 (2003)

29. S. Jacobson: Immunopathogenesis of human T cell lymphotropic virus type I-associated neurologic disease. *J Infect Dis* 186 Suppl 2, S187-S192 (2002)

30. H.C. Bastian: Special diseases of the spinal cord. 1, 1479-1483 (1882)

31. T.M. Rivers: Viruses. *JAMA* 92, 1147-1152 (1929)

32. F.R. Ford: The nervous complications of measles: with a summary of literature and publications of 12

additional case reports. *Bulletin of Johns Hopkins Hospital* 43, 140-184 (1928)

33. Morris, M.H. & A. Robbins: Acute infectious myelitis following rubella. *The Journal of Pediatrics* 23, 365-367 (1943)

34. L.A. Senseman: Myelitis complicating measles. *Archives of Neurology and Psychiatry* 53, 309-312 (1945)

35. A.I. Suchett-Kaye: Acute transverse myelitis complicating pneumonia. *The Lancet* 255, 417-(1948)

36. de Seze, J. Stojkovic, T. Breteau, G. Lucas, C. Michon-Pasturel, U. Gauvrit, J.Y. Hachulla, E. Mounier-Vehier, F. Pruvo, J.P. Leys, D. Destee, A. Hatron, P.Y. & P. Vermersch: Acute myelopathies: Clinical, laboratory and outcome profiles in 79 cases. *Brain* 124, 1509-1521 (2001)

37. Vitali, C. Bombardieri, S. Moutsopoulos, H.M. Coll, J. Gerli, R. Hatron, P.Y. Kater, L. Konttinen, Y.T. Manthorpe, R. Meyer, O. Mosca, M. Ostuni, P. Pellerito, R.A. Pennec, Y. Porter, S.R. Richards, A. Sauvezie, B. Schiodt, M. Sciuto, M. Shoenfeld, Y. Skopouli, F.N. Smolen, J.S. Soromenho, F. Tishler, M. & M.J. Wattiaux: Assessment of the European classification criteria for Sjogren's syndrome in a series of clinically defined cases: results of a prospective multicentre study. The European Study Group on Diagnostic Criteria for Sjogren's Syndrome. *Ann Rheum Dis* 55, 116-121 (1996)

38. Lockshin, M.D. Sammaritano, L.R. & S. Schwartzman: Validation of the Sapporo criteria for antiphospholipid syndrome. *Arthritis Rheum* 43, 440-443 (2000)

39. Tan, E.M. Cohen, A.S. Fries, J.F. Masi, A.T. McShane, D.J. Rothfield, N.F. Schaller, J.G. Talal, N. & R.J. Winchester: The 1982 revised criteria for the classification of systemic lupus erythematosus. *Arthritis Rheum* 25, 1271-1277 (1982)

40. Rudick, R.A. French, C.A. Breton, D. & G.W. Williams: Relative diagnostic value of cerebrospinal fluid kappa chains in MS: comparison with other immunoglobulin tests. *Neurology* 39, 964-968 (1989)

41. Hung, K.L. Chen, W.C. & C.S. Huang: Diagnostic value of cerebrospinal fluid immunoglobulin G (IgG) in pediatric neurological diseases. *J Formos Med Assoc* 90, 1055-1059 (1991)

42. Jacobs, L.D. Beck, R.W. Simon, J.H. Kinkel, R.P. Brownscheidle, C.M. Murray, T.J. Simonian, N.A. Slasor, P.J. & A.W. Sandrock: Intramuscular interferon beta-1a therapy initiated during a first demyelinating event in multiple sclerosis. CHAMPS Study Group. *N Engl J Med* 343, 898-904 (2000)

43. B. Wilske: Microbiological diagnosis in Lyme borreliosis. *Int J Med Microbiol* 291 Suppl 33, 114-119 (2002)

44. Knebusch, M. Strassburg, H.M. & K. Reiners: Acute transverse myelitis in childhood: nine cases and review of the literature. *Dev Med Child Neurol* 40, 631-639 (1998)

45. Ferch, R.D. Morgan, M.K. & W.R. Sears: Spinal arteriovenous malformations: a review with case illustrations. *J Clin Neurosci* 8, 299-304 (2001)

46. Moriarity, J.L. Clatterbuck, R.E. & D. Rigamonti: The natural history of cavernous malformations. *Neurosurg Clin N Am* 10, 411-417 (1999)

47. R.J. Wityk: Dural arteriovenous fistula of the spinal cord: an uncommon cause of myelopathy. *Semin Neurol* 16, 27-32 (1996)

48. Schreck, R.I. Manion, W.L. Kambin, P. & M. Sohn: Nucleus pulposus pulmonary embolism. A case report. *Spine* 20, 2463-2466 (1995)

49. Bots, G.T. Wattendorff, A.R. Buruma, O.J. Roos, R.A. & L.J. Endtz: Acute myelopathy caused by fibrocartilaginous emboli. *Neurology* 31, 1250-1256 (1981)

50. Toro, G. Roman, G.C. Navarro-Roman, L. Cantillo, J. Serrano, B. & I. Vergara: Natural history of spinal cord infarction caused by nucleus pulposus embolism. *Spine* 19, 360-366 (1994)

51. Case records of the Massachusetts General Hospital. Weekly clinicopathological exercises. Case 5-1991. A 61-year-old woman with an abrupt onset of paralysis of the legs and impairment of the bladder and bowel function. *N Engl J Med* 324, 322-332 (1991)

52. Okada, S. & R. Okeda: Pathology of radiation myelopathy. *Neuropathology* 21, 247-265 (2001)

53. Liu, C.Y. Yim, B.T. & A.J. Wozniak: Anticoagulation therapy for radiation-induced myelopathy. *Ann Pharmacother* 35, 188-191 (2001)

54. Glantz, M.J. Burger, P.C. Friedman, A.H. Radtke, R.A. Massey, E.W. & S.C. Schold, Jr: Treatment of radiation-induced nervous system injury with heparin and warfarin. *Neurology* 44, 2020-2027 (1994)

55. Asamoto, S. Sugiyama, H. Doi, H. Iida, M. Nagao, T. & K. Matsumoto: Hyperbaric oxygen (HBO) therapy for acute traumatic cervical spinal cord injury. *Spinal Cord* 38, 538-540 (2000)

56. Calabro, F. & J.R. Jinkins: MRI of radiation myelitis: a report of a case treated with hyperbaric oxygen. *Eur Radiol* 10, 1079-1084 (2000)

57. Angibaud, G. Ducasse, J.L. Baille, G. & M. Clanet: [Potential value of hyperbaric oxygenation

in the treatment of post-radiation myelopathies]. *Rev Neurol (Paris)* 151, 661-666 (1995)

58. Ford, B. Tampieri, D. & G. Francis: Long-term follow-up of acute partial transverse myelopathy. *Neurology* 42, 250-252 (1992)

59. Miller, D.H. Ormerod, I.E. Rudge, P. Kendall, B.E. Moseley, I.F. & W.I. McDonald: The early risk of multiple sclerosis following isolated acute syndromes of the brainstem and spinal cord. *Ann Neurol* 26, 635-639 (1989)

60. Ungurean, A. Palfi, S. Dibo, G. Tiszlavicz, L. & L. Vecsei: Chronic recurrent transverse myelitis or multiple sclerosis. *Funct Neurol* 11, 209-214 (1996)

61. Scott, T.F. Bhagavatula, K. Snyder, P.J. & C. Chieffe: Transverse myelitis. Comparison with spinal cord presentations of multiple sclerosis. *Neurology* 50, 429-433 (1998)

62. Bakshi, R. Kinkel, P.R. Mechtler, L.L. Bates, V.E. Lindsay, B.D. Esposito, S.E. & W.R. Kinkel: Magnetic resonance imaging findings in 22 cases of myelitis: comparison between patients with and without multiple sclerosis. *Eur J Neurol* 5, 35-48 (1998)

63. McDonald, W.I. Compston, A. Edan, G. Goodkin, D. Hartung, H.P. Lublin, F.D. McFarland, H.F. Paty, D.W. Polman, C.H. Reingold, S.C. Sandberg-Wollheim, M. Sibley, W. Thompson, A. van den, N.S. Weinshenker, B.Y. & J.S. Wolinsky: Recommended diagnostic criteria for multiple sclerosis: guidelines from the International Panel on the diagnosis of multiple sclerosis. *Ann Neurol* 50, 121-127 (2001)

64. O'Riordan, J.I. Losseff, N.A. Phatouros, C. Thompson, A.J. Moseley, I.F. MacManus, D.G. McDonald, W.I. & D.H. Miller: Asymptomatic spinal cord lesions in clinically isolated optic nerve, brain stem, and spinal cord syndromes suggestive of demyelination. *J Neurol Neurosurg Psychiatry* 64, 353-357 (1998)

65. Paine, R.S. & R.K. Byers: Transverse myelopathy in childhood. *AMA American Journal of Diseases of Children* 85, 151-163 (1968)

66. Pidcock F Krishnan C & D.A. Kerr: Acute transverse myelitis in childhood: Center based analysis of 40 children. *(Manuscript in review)* (2003)

67. Dunne, K. Hopkins, I.J. & L.K. Shield: Acute transverse myelopathy in childhood. *Dev Med Child Neurol* 28, 198-204 (1986)

68. Burns, A.S. Rivas, D.A. & J.F. Ditunno: The management of neurogenic bladder and sexual dysfunction after spinal cord injury. *Spine* 26, S129-S136 (2001)

69. DasGupta, R. & C.J. Fowler: Sexual and urological dysfunction in multiple sclerosis: better understanding and improved therapies. *Curr Opin Neurol* 15, 271-278 (2002)

70. Patten, S.B. & L.M. Metz: Depression in multiple sclerosis. *Psychother Psychosom* 66, 286-292 (1997)

71. al Deeb, S.M. Yaqub, B.A. Bruyn, G.W. & N.M. Biary: Acute transverse myelitis. A localized form of postinfectious encephalomyelitis. *Brain* 120 (Pt 7), 1115-1122 (1997)

72. Hummers, L.K. Krishnan, C. Casciola-Rosen, L. Rosen, A. Morris, S. Mahoney, J.A. Kerr, D.A. & F.M. Wigley: Recurrent Transverse Myelitis Associates with Anti-Ro (SSA) Autoantibodies. *Neurology* (2003) (in press)

73. Kaplin, A.I. Krishnan, C. Darman, J.S. Deshpande, D.M. Harper, J.M. Shats, I. Pardo, C.A. Gijbels, K. Calabresi, P.A. & D.A. Kerr: Spinal Fluid Interleukin-6 Levels in Transverse Myelitis: Correlation with Nitric oxide generation and Clinical Disability. *Lancet* (2003) (in review)

74. Irani, D.N. & D.A. Kerr: 14-3-3 protein in the cerebrospinal fluid of patients with acute transverse myelitis. *Lancet* 355, 901-(2000)

75. Nagaswami, S. Kepes, J. Foster, D.B. & S.W. Twemlow: Necrotizing myelitis: a clinico-pathologic report of two cases associated with diplococcus pneumoniae and mycoplasma pneumoniae infections. *Trans Am Neurol Assoc* 98, 290-292 (1973)

76. Mirich, D.R. Kucharczyk, W. Keller, M.A. & J. Deck: Subacute necrotizing myelopathy: MR imaging in four pathologically proved cases. *AJNR Am J Neuroradiol* 12, 1077-1083 (1991)

77. Katz, J.D. & A.H. Ropper: Progressive necrotic myelopathy: clinical course in 9 patients. *Arch Neurol* 57, 355-361 (2000)

78. de Macedo, D.D. de Mattos, J.P. & T.M. Borges: [Transverse myelopathy and systemic lupus erythematosus. Report of a case and review of the literature]. *Arq Neuropsiquiatr* 37, 76-84 (1979)

79. Goodyear, C.S. O'Hanlon, G.M. Plomp, J.J. Wagner, E.R. Morrison, I. Veitch, J. Cochrane, L. Bullens, R.W. Molenaar, P.C. Conner, J. & H.J. Willison: Monoclonal antibodies raised against Guillain-Barre syndrome-associated Campylobacter jejuni lipopolysaccharides react with neuronal gangliosides and paralyze muscle-nerve preparations. *J Clin Invest* 104, 697-708 (1999)

80. Plomp, J.J. Molenaar, P.C. O'Hanlon, G.M. Jacobs, B.C. Veitch, J. Daha, M.R. Van Doorn, P.A. Van der Meche, F.G. Vincent, A. Morgan, B.P. & H.J. Willison: Miller Fisher anti-GQ1b antibodies: alpha-latrotoxin-like effects on motor end plates. *Ann Neurol* 45, 189-199 (1999)

81. O'Hanlon, G.M. Paterson, G.J. Veitch, J. Wilson, G. & H.J. Willison: Mapping immunoreactive epitopes in the

human peripheral nervous system using human monoclonal anti-GM1 ganglioside antibodies. *Acta Neuropathol (Berl)* 95, 605-616 (1998)

82. Olson, J.K. Eagar, T.N. & S.D. Miller: Functional activation of myelin-specific T cells by virus-induced molecular mimicry. *J Immunol* 169, 2719-2726 (2002)

83. Levin, M.C. Lee, S.M. Kalume, F. Morcos, Y. Dohan, F.C., Jr. Hasty, K.A. Callaway, J.C. Zunt, J. Desiderio, D. & J.M. Stuart: Autoimmunity due to molecular mimicry as a cause of neurological disease. *Nat Med* 8, 509-513 (2002)

84. Williamson, R.A. Burgoon, M.P. Owens, G.P. Ghausi, O. Leclerc, E. Firme, L. Carlson, S. Corboy, J. Parren, P.W. Sanna, P.P. Gilden, D.H. & D.R. Burton: Anti-DNA antibodies are a major component of the intrathecal B cell response in multiple sclerosis. *Proc Natl Acad Sci U S A* 98, 1793-1798 (2001)

85. DeGiorgio, L.A. Konstantinov, K.N. Lee, S.C. Hardin, J.A. Volpe, B.T. & B. Diamond: A subset of lupus anti-DNA antibodies cross-reacts with the NR2 glutamate receptor in systemic lupus erythematosus. *Nat Med* 7, 1189-1193 (2001)

86. Kotzin, B.L. Leung, D.Y. Kappler, J. & P. Marrack: Superantigens and their potential role in human disease. *Adv Immunol* 54, 99-166 (1993)

87. Vanderlugt, C.L. Begolka, W.S. Neville, K.L. Katz-Levy, Y. Howard, L.M. Eagar, T.N. Bluestone, J.A. & S.D. Miller: The functional significance of epitope spreading and its regulation by co-stimulatory molecules. *Immunol Rev* 164, 63-72 (1998)

88. Kaplin, A.I. Krishnan, C. Backovic, S. Calabresi, P.A. & D.A. Kerr: Interleukin-6 mediates inflammatory spinal cord injury by stimulating nitric oxide production. *Nature Medicine* (2003) (in review)

89. Elovaara, I. Lalla, M. Spare, E. Lehtimaki, T. & P. Dastidar: Methylprednisolone reduces adhesion molecules in blood and cerebrospinal fluid in patients with MS. *Neurology* 51, 1703-1708 (1998)

90. Sellebjerg, F. Christiansen, M. Jensen, J. & J.L. Frederiksen: Immunological effects of oral high-dose methylprednisolone in acute optic neuritis and multiple sclerosis. *Eur J Neurol* 7, 281-289 (2000)

91. Williams, C.S. Butler, E. & G.C. Roman: Treatment of myelopathy in Sjogren syndrome with a combination of prednisone and cyclophosphamide. *Arch Neurol* 58, 815-819 (2001)

92. Dumas, J.L. Valeyre, D. Chapelon-Abric, C. Belin, C. Piette, J.C. Tandjaoui-Lambiotte, H. Brauner, M. & D. Goldlust: Central nervous system sarcoidosis: follow-up at MR imaging during steroid therapy. *Radiology* 214, 411-420 (2000)

93. Bracken, M.B. Shepard, M.J. Collins, W.F. Holford, T.R. Young, W. Baskin, D.S. Eisenberg, H.M. Flamm, E. Leo-Summers, L. & J. Maroon: A randomized, controlled trial of methylprednisolone or naloxone in the treatment of acute spinal-cord injury. Results of the Second National Acute Spinal Cord Injury Study. *N Engl J Med* 322, 1405-1411 (1990)

94. Defresne, P. Meyer, L. Tardieu, M. Scalais, E. Nuttin, C. De Bont, B. Loftus, G. Landrieu, P. Kadhim, H. & G. Sebire: Efficacy of high dose steroid therapy in children with severe acute transverse myelitis. *J Neurol Neurosurg Psychiatry* 71, 272-274 (2001)

95. Lahat, E. Pillar, G. Ravid, S. Barzilai, A. Etzioni, A. & E. Shahar: Rapid recovery from transverse myelopathy in children treated with methylprednisolone. *Pediatr Neurol* 19, 279-282 (1998)

96. Sebire, G. Hollenberg, H. Meyer, L. Huault, G. Landrieu, P. & M. Tardieu: High dose methylprednisolone in severe acute transverse myelopathy. *Arch Dis Child* 76, 167-168 (1997)

97. Kennedy, P.G. & A.I. Weir: Rapid recovery of acute transverse myelitis treated with steroids. *Postgrad Med J* 64, 384-385 (1988)

98. Kalita, J. & U.K. Misra: Is methyl prednisolone useful in acute transverse myelitis? *Spinal Cord* 39, 471-476 (2001)

99. B.G. Weinshenker: Plasma exchange for severe attacks of inflammatory demyelinating diseases of the central nervous system. *J Clin Apheresis* 16, 39-42 (2001)

100. B.G. Weinshenker: Therapeutic plasma exchange for acute inflammatory demyelinating syndromes of the central nervous system. *J Clin Apheresis* 14, 144-148 (1999)

101. Weinshenker, B.G. O'Brien, P.C. Petterson, T.M. Noseworthy, J.H. Lucchinetti, C.F. Dodick, D.W. Pineda, A.A. Stevens, L.N. & M. Rodriguez: A randomized trial of plasma exchange in acute central nervous system inflammatory demyelinating disease. *Ann Neurol* 46, 878-886 (1999)

102. Keegan, M. Pineda, A.A. McClelland, R.L. Darby, C.H. Rodriguez, M. & B.G. Weinshenker: Plasma exchange for severe attacks of CNS demyelination: Predictors of response. *Neurology* 58, 143-146 (2002)

103. Wollinsky, K.H. Hulser, P.J. Brinkmeier, H. Aulkemeyer, P. Bossenecker, W. Huber-Hartmann, K.H. Rohrbach, P. Schreiber, H. Weber, F. Kron, M. Buchele, G. Mehrkens, H.H. Ludolph, A.C. & R. Rudel: CSF filtration is an effective treatment of Guillain-Barre syndrome: a randomized clinical trial. *Neurology* 57, 774-780 (2001)

104. Robinson, W.H. Steinman, L. & P. J. Utz: Protein arrays for autoantibody profiling and fine-specificity mapping. *Proteomics* 3, 2077-2084 (2003)

105. Robinson, W.H. Fontoura, P. Lee, B.J. de Vegvar, H.E. Tom, J. Pedotti, R. DiGennaro, C.D. Mitchell, D.J. Fong, D. Ho, P.P. Ruiz, P.J. Maverakis, E. Stevens, D.B.

Bernard, C.C. Martin, R. Kuchroo, V.K. van Noort, J.M. Genain, C.P. Amor, S. Olsson, T. Utz, P.J. Garren, H. & L. Steinman: Protein microarrays guide tolerizing DNA vaccine treatment of autoimmune encephalomyelitis. *Nat Biotechnol* 21, 1033-1039 (2003)

106. Mohan, N. Edwards, E.T. Cupps, T.R. Oliverio, P.J. Sandberg, G. Crayton, H. Richert, J.R. & J.N. Siegel: Demyelination occurring during anti-tumor necrosis factor alpha therapy for inflammatory arthritides. *Arthritis Rheum* 44, 2862-2869 (2001)

107. Mastaglia, F.L. & B.A. Phillips: Idiopathic inflammatory myopathies: epidemiology, classification, and diagnostic criteria. *Rheum Dis Clin North Am* 28, 723-741 (2002)

108. R.A. Hughes: Management of chronic inflammatory demyelinating polyradiculoneuropathy. *Drugs* 63, 275-287 (2003)

109. M.C. Dalakas: Mechanisms of action of IVIg and therapeutic considerations in the treatment of acute and chronic demyelinating neuropathies. *Neurology* 59, S13-S21 (2002)

110. J.W. Chan: Optic neuritis in multiple sclerosis. *Ocul Immunol Inflamm* 10, 161-186 (2002)

111. Darnell, R.B. & J.B. Posner: Paraneoplastic syndromes involving the nervous system. *N Engl J Med* 349, 1543-1554 (2003)

112. Bataller, L. & J. Dalmau: Paraneoplastic neurologic syndromes: approaches to diagnosis and treatment. *Semin Neurol* 23, 215-224 (2003)

113. R.C. Dale: Acute disseminated encephalomyelitis. *Semin Pediatr Infect Dis* 14, 90-95 (2003)

114. Granata, T. Gobbi, G. Spreafico, R. Vigevano, F. Capovilla, G. Ragona, F. Freri, E. Chiapparini, L. Bernasconi, P. Giordano, L. Bertani, G. Casazza, M. Dalla, B.B. & L. Fusco: Rasmussen's encephalitis: early characteristics allow diagnosis. *Neurology* 60, 422-425 (2003)

115. Bien, C.G. Widman, G. Urbach, H. Sassen, R. Kuczaty, S. Wiestler, O.D. Schramm, J. & C.E. Elger: The natural history of Rasmussen's encephalitis. *Brain* 125, 1751-1759 (2002)

Key Words: Transverse myelopathy, Transverse myelitis, Neuroimmunologic disorders, Interleukin-6, Review

Send correspondence to: Chitra Krishnan, M.H.S., Johns Hopkins Transverse Myelitis Center, Path 627 C, 600 N. Wolfe Street, Baltimore, MD 21287, Tel: 410-955-3129, Fax: 410-502-6736, E-mail: ckrishn1@jhmi.edu