

## Ultrasonography in the diagnosis of Hashimoto's thyroiditis

Guihua Wu<sup>1</sup>, Dazhong Zou<sup>2</sup>, Haiyun Cai<sup>1</sup>, Yajun Liu<sup>1</sup>

<sup>1</sup>Department of Ultrasound, Suzhou Wuzhong Peoples's Hospital, Suzhou, China, <sup>2</sup>Department of Ultrasound, Jiangyin Hospital Affiliated of South-East University, Jiangyin, China

### TABLE OF CONTENTS

1. Abstract
2. Introduction
3. Ultrasonographic characteristics in Hashimoto's thyroiditis
4. Ultrasonography in differential diagnosis of Hashimoto's thyroiditis from other thyroid diseases
5. Ultrasonography for diagnosis of Hashimoto's thyroiditis coexistence of other diseases
6. Conclusion
7. Acknowledgements
8. References

### 1. ABSTRACT

Hashimoto's thyroiditis is an autoimmune thyroid disease with an increasing prevalence in the past few decades. The diagnosis of Hashimoto's thyroiditis has been traditionally based on clinical presentation, fine needle aspiration, biopsy, and laboratory findings. Here, we discuss the recent advantages of ultrasonography for establishing the diagnosis of Hashimoto's thyroiditis. Moreover, ultrasound-guided fine-needle biopsy is being used more often in the differential diagnosis of thyroid nodules of Hashimoto's thyroiditis from other thyroid disorders. Together, ultrasound is emerging as a noninvasive method that with fine-needle aspiration aids in the diagnosis of Hashimoto's thyroiditis.

### 2. INTRODUCTION

Hashimoto's thyroiditis, also known as chronic lymphocytic thyroiditis, is a type of autoimmune thyroid disease, in which the thyroid gland is attacked by various antibody- and cell-mediated immune processes (1). In North America, prevalence of Hashimoto's thyroiditis is 10%–15%, making it the most common cause of primary hypothyroidism (2), while its prevalence in Europe and Asia has been increasing in the past few decades. For instance, prevalence of Hashimoto's thyroiditis increased from 2.3% in 1994 to 3.8% in 2001 in Scotland (3), and from 1.0% in 1998 to 3.9% in 2010 among individuals aged over 30 years in Korea (4). Hashimoto's thyroiditis mostly occurs in women aged between 30 and 60 years, but also can occur in children (5). This disease can lead to symptomatic thyroid dysfunction as well as subclinical hypothyroidism and chronic autoimmune thyroiditis, ultimately progressing to thyroid failure (5).

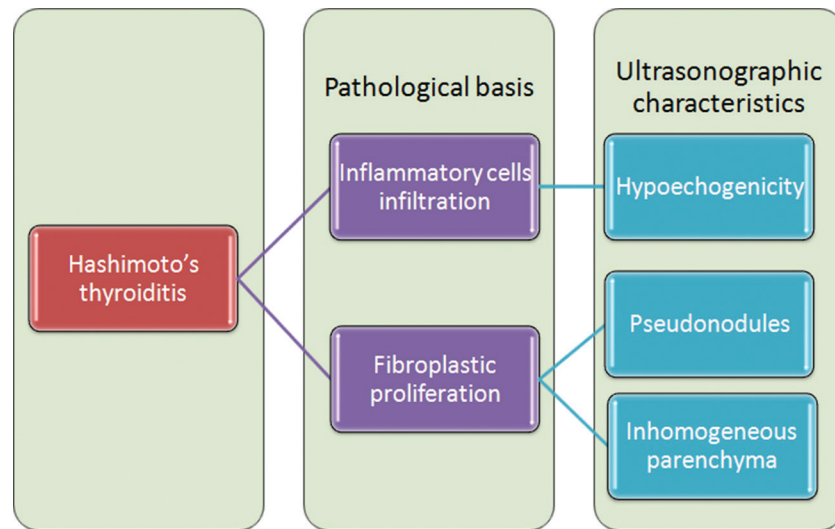
In diagnosis, evaluation, and management of Hashimoto's thyroiditis, ultrasonography (or sonography) is an essential noninvasive tool to help therapists

make clinical decisions (6). Studies have shown that echogenicity on ultrasonography is a reliable standard to confirm diagnosis or determine therapeutic efficacy (7-10). Color flow Doppler ultrasonography is used to examine the intrathyroidal vascular area (11), while high-resolution ultrasonography is used to measure the diameter of the brachial artery (12,13). Moreover, ultrasonography or Doppler sonography is a useful tool for distinguishing cases of Hashimoto's thyroiditis comorbid with other disorders (14,15). Even in studies investigating the association between Hashimoto's thyroiditis and other disorders, such as oral lichen planus, obstructive sleep apnea, and vitamin D deficiency, thyroid ultrasonography is a helpful tool for diagnosis (16-18).

In addition to providing ultrasonographic thyroid changes, ultrasound-guided fine-needle biopsy is a minimally invasive method for pathologic diagnosis of Hashimoto's thyroiditis, even in children (19). Fine-needle aspiration is a standard method to distinguish whether or not a thyroid nodule is malignant, and has a sensitivity of 54%–90% and specificity of 60%–90% for detecting malignant lesions (20). Even in difficult to diagnose cases, ultrasound-guided fine-needle biopsy is an effective tool to confirm accurate diagnosis of Hashimoto's thyroiditis (21,22). In this review, we will discuss ultrasonography for diagnosis of Hashimoto's thyroiditis, focusing on its ultrasonographic characteristics.

### 3. ULTRASONOGRAPHIC CHARACTERISTICS OF HASHIMOTO'S THYROIDITIS

In the pathophysiology of Hashimoto's thyroiditis, thyrocyte destruction by antibody- or immune cell-mediated cytotoxicity leads to morphologic and microscopic changes, including enlargement of the thyroid,



**Figure 1.** Ultrasonographic characteristics and their pathological basis in Hashimoto's thyroiditis. The hypoechogenicity in ultrasonography of Hashimoto's thyroiditis is due to inflammatory cell infiltration in the thyroid. The pathological basis of pseudonodules and inhomogeneous parenchyma is fibroplastic proliferation.

parenchymal infiltration by inflammatory cells, fibroplastic proliferation, calcification, and vascular proliferation. These changes are the basis of the ultrasonographic characteristics of Hashimoto's thyroiditis. Mazziotti and colleagues (23) analyzed 89 patients with Hashimoto's thyroiditis and 40 healthy controls, and found that thyroid echogenicity evaluated by gray-scale quantitative analysis was lower in patients with the disease, and that thyroid hypoechogenicity was associated with occurrence of hypothyroidism in the patients (23). Even in cases with difficult diagnosis, hypoechogenicity was valuable for clarifying diagnosis (24). This association may be due to the pathologic basis of hypoechogenicity, wherein inflammatory cells infiltrate into the thyroid. In addition to hypoechogenicity, pseudonodules and inhomogeneous parenchyma have been observed in patients with Hashimoto's thyroiditis (25,26), which may be related to fibroplastic proliferation (Figure 1). In recent years, a computer-aided diagnostic technique has been applied in thyroid ultrasonography. The gray-scale features and classifiers of this technique can provide objective and reproducible differentiation between Hashimoto's thyroiditis and normal conditions with an accuracy of 80%, sensitivity of 76%, specificity of 84%, and positive predictive value of 83.3% for detection of Hashimoto's thyroiditis (27).

Hashimoto's thyroiditis affects 1.3% of children (28,29). In children with Hashimoto's thyroiditis, 37% demonstrate sonographic thyroid changes, while 50% with normal thyroid findings initially will develop changes within seven months (30). These sonographic changes may primarily be due to goiter (30). However, in some cases, classic sonographic findings may not develop for over four years. An exciting advantage

of ultrasonography is that the resistive index in color Doppler may be more sensitive than other parameters for diagnosis of Hashimoto's thyroiditis in children (31). In one case report of a 12-year-old girl with Hashimoto's thyroiditis, some rare findings were observed on ultrasonography, including serial changes that went from early features of inflammation to severe features of end-stage Hashimoto's thyroiditis, which then returned to almost normal with only minimal features of inflammation, paralleling changes in thyroid function (32).

In the case of a 59-year-old woman with hypothyroidism, color flow Doppler sonography detected a solid hypervascularized nodule, assisting in diagnosis of Hashimoto's thyroiditis (33), and reflecting the significant role of color flow Doppler in diagnosis of this disease. Doppler measurements can enhance sonography by assessing the frequency shift of blood flow (34). On color Doppler ultrasonography of the thyroid, vascularity types (including hypovascularity), marked internal flow, and focal thyroid inferno may be observed in Hashimoto's thyroiditis, among which "focal thyroid inferno" may be an indicator of focal Hashimoto's thyroiditis with a diagnostic sensitivity and specificity of 7.7% and 100%, respectively (35). Later, Fu and colleagues (36) confirmed this finding that "focal inferno" may be a characteristic of the disease on color Doppler ultrasonography. Recently, a study including 144 patients with Hashimoto's thyroiditis found heterogeneous echotexture with increased vascularity in the majority of patients (37), suggesting a novel characteristic on ultrasonography. Wu and colleagues (38) confirmed this finding and proposed that an ovoid-to-round shape, well-defined boundary, and hypervascularity may be associated with focal Hashimoto's thyroiditis. Increased blood flow

in the hypoechoic lesions also can be used to monitor recurrence of Hashimoto's thyroiditis (39). However, Hashimoto's thyroiditis cannot be detected based on blood flow in all patients with the disease. In some cases, a hypoechoic area may appear, but without blood flow in that area (40). Thus, diagnosis of Hashimoto's thyroiditis cannot be excluded when blood flow is not detected on color Doppler. Multiple sonographic characteristics should be considered in atypical cases.

In cases with difficult nodular diagnosis, ultrasound-guided fine-needle biopsy is an effective minimally invasive method to elucidate the nature of the lesion and determine the therapeutic strategy (41,42). Even in a new variant of the disease, immunoglobulin G4-related Hashimoto's thyroiditis, ultrasound-guided fine-needle biopsy can provide evidence for diagnosis (43).

#### 4. ULTRASONOGRAPHY FOR DIFFERENTIATION OF HASHIMOTO'S THYROIDITIS FROM OTHER THYROID DISEASES

As an essential tool for diagnosis of Hashimoto's thyroiditis, ultrasonography plays a crucial role in differentiating between Hashimoto's thyroiditis and other thyroid disorders. For example, when distinguishing Hashimoto's thyroiditis from Graves' disease, which have a similar thyroid echographic pattern on ultrasonography, color flow Doppler sonography could provide valuable evidence of diffusely increased thyroid blood flow (44). In addition to benign diseases, differential diagnosis between Hashimoto's thyroiditis and thyroid cancer is more common in patients with thyroid nodules. Therefore, ultrasonography combined with color flow Doppler sonography is effective for studying differential diagnoses (45).

When ultrasonography cannot distinguish Hashimoto's thyroiditis from other thyroid diseases, ultrasound-guided fine-needle aspiration cytology can be helpful (46). In some cases of Hashimoto's thyroiditis and other diseases involving the neck, such as neurofibromatosis type 1, mucosa-associated lymphoid tissue lymphoma, or Bethesda grade III nodules, ultrasound-guided fine-needle aspiration cytology could help provide evidence of Hashimoto's thyroiditis for accurate diagnosis (47-49).

#### 5. ULTRASONOGRAPHY FOR DIAGNOSIS OF HASHIMOTO'S THYROIDITIS COEXISTING WITH OTHER DISEASES

When Hashimoto's thyroiditis coexists with thyroid nodules, diagnosis may be complex and difficult. Even though some cases can be diagnosed by using noninvasive ultrasonography (50), ultrasound-guided

fine-needle biopsy has been reported to be a valuable method for accurate diagnosis of Hashimoto's thyroiditis coexisting with other thyroid disorders in a large series of patients (51,52) and in some cases with difficult diagnosis (53-55).

Although fine-needle aspiration biopsy plays a crucial role in diagnosis of thyroid nodules, recent studies have focused on noninvasive ultrasound-based methods for diagnosis of Hashimoto's thyroiditis under complex conditions to supplement fine-needle aspiration. Acoustic radiation force impulse (ARFI) is a new modality to evaluate tissue stiffness quantitatively. Liu and colleagues (56) found that ARFI elastography is an effective method to distinguish between benign and malignant thyroid nodules in patients with Hashimoto's thyroiditis. Virtual touch tissue quantification (VTQ) involves quantitative implementation of ARFI, and provides objective numerical evaluation of tissue stiffness in order to evaluate thyroid nodules (57,58). In a preliminary study with 118 subjects, VTQ technology was shown to be useful for differentiating between malignant and benign thyroid nodules coexisting with Hashimoto's thyroiditis (59). This study further found that 2.75 m/s may be the best cut-off point for shear wave velocity between malignant and benign thyroid nodules.

In addition, contrast-enhanced ultrasonography, which applies contrast medium to traditional medical sonography, has been found to improve diagnostic accuracy of thyroid nodules coexisting with Hashimoto's thyroiditis (60). This noninvasive ultrasound-based method may lead to a tendency of using ultrasonography for diagnosis of thyroid disorders. As computer technology is developed, computer-aided diagnostic techniques in ultrasonography will provide additional novel methods with improved diagnostic accuracy, sensitivity, and specificity.

#### 6. CONCLUSION

In conclusion, ultrasonography is an essential tool for diagnosis of Hashimoto's thyroiditis. Color flow Doppler could further help to diagnose Hashimoto's thyroiditis based on "focal thyroid inferno." However, when Hashimoto's thyroiditis coexists with other thyroid disorders or is difficult to distinguish from other diseases, noninvasive ultrasound-based methods may be insufficient. At this time, ultrasound-guided fine-needle biopsy is an effective choice. Although there is no doubt that ultrasound-guided fine-needle aspiration cytology plays a crucial role in diagnosis of Hashimoto's thyroiditis, noninvasive methods may be preferred in the future. Recent studies have found that certain noninvasive ultrasound-based methods, which supplement fine-needle aspiration, are able to improve diagnostic accuracy of Hashimoto's thyroiditis. New insights into development of noninvasive ultrasound-based methods

will be aided by novel computer technology to further improve diagnosis of Hashimoto's thyroiditis and other thyroid disorders.

## 7. ACKNOWLEDGEMENTS

This work was supported by Doctor Xuedong Deng at Suzhou Municipal Hospital.

## 8. REFERENCES

1. Hiromatsu Y, Satoh H, Amino N: Hashimoto's thyroiditis: history and future outlook. *Hormones (Athens)* 12(1):12-8 (2013)
2. Kumar, Vinay. 24: The Endocrine System. Robbins and Cotran Pathologic Mechanisms of Disease (8<sup>th</sup> ed.) Philadelphia, PA: Elsevier. pp. 1111–205 (2010)
3. Leese GP, Flynn RV, Jung RT, Macdonald TM, Murphy MJ, Morris AD: Increasing prevalence and incidence of thyroid disease in Tayside, Scotland: the Thyroid Epidemiology Audit and Research Study (TEARS) *Clin Endocrinol (Oxf)* 68(2):311-6 (2008)
4. Statistics Korea: Available: <http://kosis.kr/> Accessed 2 January 2013.
5. Fabrizio Monaco: Thyroid Diseases. Taylor and Francis. pp. 78 (2012)  
DOI: 10.1201/b12117
6. Kangelaris GT, Kim TB, Orloff LA: Role of ultrasound in thyroid disorders. *Otolaryngol Clin North Am* 43(6):1209-27, vi (2010)
7. Reinhardt W, Luster M, Rudorff KH, Heckmann C, Petrasch S, Lederbogen S, *et al*: Effect of small doses of iodine on thyroid function in patients with Hashimoto's thyroiditis residing in an area of mild iodine deficiency. *Eur J Endocrinol* 139(1):23-8 (1998)  
DOI: 10.1530/eje.0.1390023
8. Tajiri J: Radioactive iodine therapy for goitrous Hashimoto's thyroiditis. *J Clin Endocrinol Metab* 91(11):4497-500 (2006)  
DOI: 10.1210/jc.2006-1163
9. Siemińska L, Wojciechowska C, Kos-Kudła B, Marek B, Kajdaniuk D, Nowak M, *et al*: Serum concentrations of leptin, adiponectin, and interleukin-6 in postmenopausal women with Hashimoto's thyroiditis. *Endokrynol Pol* 61(1):112-6 (2010)
10. Schmidt M, Voell M, Rahlff I, Dietlein M, Kobe C, Faust M, Schicha H: Long-term follow-up of antithyroid peroxidase antibodies in patients with chronic autoimmune thyroiditis (Hashimoto's thyroiditis) treated with levothyroxine. *Thyroid* 18(7):755-60 (2008)  
DOI: 10.1089/thy.2008.0008
11. Iitaka M, Miura S, Yamanaka K, Kawasaki S, Kitahama S, Kawakami Y, *et al*: Increased serum vascular endothelial growth factor levels and intrathyroidal vascular area in patients with Graves' disease and Hashimoto's thyroiditis. *J Clin Endocrinol Metab* 83(11):3908-12 (1998)
12. Xiang GD, He YS, Zhao LS, Hou J, Yue L, Xiang HJ: Impairment of endothelium-dependent arterial dilation in Hashimoto's thyroiditis patients with euthyroidism. *Clin Endocrinol (Oxf)* 64(6):698-702 (2006)  
DOI: 10.1111/j.1365-2265.2006.02531.x
13. Xiang G, Xiang L, Xiang L, Wang H, Dong J: Change of plasma osteoprotegerin and its association with endothelial dysfunction before and after exercise in Hashimoto's thyroiditis with euthyroidism. *Exp Clin Endocrinol Diabetes* 120(9):529-34 (2012)  
DOI: 10.1055/s-0032-1323806
14. Cizmić M, Ignjatović M, Cerović S, Ajdinović B: Coexistence of Hashimoto's thyroiditis and papillary thyroidal carcinoma with papillary carcinoma of thyroglossal duct. *Vojnosanit Pregl* 64(10):714-8 (2007)  
DOI: 10.2298/VSP0710714C
15. Takashima S, Takayama F, Wang Q, Kobayashi S, Sone S: Thyroid metastasis from rectal carcinoma coexisting with Hashimoto's thyroiditis: gray-scale and power Doppler sonographic findings. *J Clin Ultrasound* 26(7):361-5 (1998)  
DOI: 10.1002/(SICI)1097-0096(199809)26:7<361:AID-JCU7>3.0.CO;2-7
16. Lo Muzio L, Santarelli A, Campisi G, Lacaia M, Favia G: Possible link between Hashimoto's thyroiditis and oral lichen planus: a novel association found. *Clin Oral Invest* 17(1):333-6 (2013)  
DOI: 10.1007/s00784-012-0767-4
17. Bozkurt NC, Karbek B, Cakal E, Firat H, Ozbek M, Delibasi T: The association between severity of obstructive sleep apnea and prevalence of Hashimoto's thyroiditis. *Endocr J* 59(11):981-8 (2012)  
DOI: 10.1507/endocrj.EJ12-0106



18. Bozkurt NC, Karbek B, Ucan B, Sahin M, Cakal E, Ozbek M, Delibasi T: The association between severity of vitamin D deficiency and Hashimoto's thyroiditis. *Endocr Pract* 19(3):479-84 (2013)  
DOI: 10.4158/EP12376.OR
19. Radetti G, Paganini C, Gentili L, Bernasconi S, Betterle C, Borkenstein M, *et al*: Frequency of Hashimoto's thyroiditis in children with type 1 diabetes mellitus. *Acta Diabetol* 32(2):121-4 (1995)  
DOI: 10.1007/BF00569570
20. Berker D, Aydin Y, Ustun I: The value of fine-needle aspiration biopsy in subcentimeter thyroid nodules. *Thyroid* 18:603-608 (2008)  
DOI: 10.1089/thy.2007.0313
21. Schmid DT, Kneifel S, Stoeckli SJ, Padberg BC, Merrill G, Goerres GW: Increased 18F-FDG uptake mimicking thyroid cancer in a patient with Hashimoto's thyroiditis. *Eur Radiol* 13(9):2119-21 (2003)  
DOI: 10.1007/s00330-002-1619-4
22. Geisinger KR, Hartle EO, Warren T: Eosinophilic replacement infiltrates in cystic Hashimoto's thyroiditis: a potential diagnostic pitfall. *Endocr Pathol* 25(3):332-8 (2014)  
DOI: 10.1007/s12022-014-9304-0
23. Mazziotti G(1), Sorvillo F, Iorio S, Carbone A, Romeo A, Piscopo M, *et al*: Grey-scale analysis allows a quantitative evaluation of thyroid echogenicity in the patients with Hashimoto's thyroiditis. *Clin Endocrinol (Oxf)* 59(2):223-9 (2003)  
DOI: 10.1046/j.1365-2265.2003.01829.x
24. Zantour B, Sfar MH, Alaya W, Chebbi W, Chatti K, Jerbi S: Hashimoto's thyroiditis and severe hypothyroidism, associated with a single hot nodule. *Rev Esp Med Nucl* 30(5):317-9 (2011)  
DOI: 10.1016/j.remn.2010.10.011
25. Lorini R, Gastaldi R, Traggiai C, Perucchin PP: Hashimoto's Thyroiditis. *Pediatr Endocrinol Rev* 1 Suppl 2:205-11; discussion 211 (2003)
26. Fink H, Hintze G: Autoimmune thyroiditis (Hashimoto's thyroiditis): current diagnostics and therapy. *Med Klin (Munich)* 105(7):485-93 (2010)  
DOI: 10.1007/s00063-010-1082-y
27. Acharya UR, Vinitha Sree S, Mookiah MR, Yantri R, Molinari F, Zieleznik W, *et al*: Diagnosis of Hashimoto's thyroiditis in ultrasound using tissue characterization and pixel classification. *Proc Inst Mech Eng H* 227(7):788-98 (2013)  
DOI: 10.1177/0954411913483637
28. Babcock DS: Thyroid disease in the pediatric patient: emphasizing imaging with sonography. *Pediatr Radiol* 36(4):299-308, quiz 372-3 (2006)  
DOI: 10.1007/s00247-005-0062-5
29. Pearce EN, Farwell AP, Braverman LE: Thyroiditis. *N Engl J Med* 348(26):2646-55 (2003)  
DOI: 10.1056/NEJMra021194
30. Vlachopapadopoulou E, Thomas D, Karachaliou F, Chatzimarkou F, Memalal L, Vakaki M, *et al*: Evolution of sonographic appearance of the thyroid gland in children with Hashimoto's thyroiditis. *J Pediatr Endocrinol Metab* 22(4):339-44 (2009)  
DOI: 10.1515/JPEM.2009.22.4.339
31. Sarikaya B, Demirbilek H, Akata D, Kandemir N: The role of the resistive index in Hashimoto's thyroiditis: a sonographic pilot study in children. *Clinics (Sao Paulo)* 67(11):1253-7 (2012)  
DOI: 10.6061/clinics/2012(11)05
32. Nanan R, Wall JR: Remission of Hashimoto's thyroiditis in a twelve-year-old girl with thyroid changes documented by ultrasonography. *Thyroid* 20(10):1187-90 (2010)  
DOI: 10.1089/thy.2010.0102
33. Zengi A, Karadeniz M, Demirpolat G, Akgun A, Karakose S, Yilmaz C: Hypothyroid Hashimoto's thyroiditis with scintigraphic and color flow Doppler sonography features mimicking a hot nodule. *Intern Med* 48(4):231-4 (2009)  
DOI: 10.2169/internalmedicine.48.1638
34. Claude Franceschi: L'Investigation vasculaire par ultrasonographie doppler. *Masson*. (1978)
35. Fu X, Guo L, Zhang H, Ran W, Fu P, Li Z, *et al*: "Focal thyroid inferno" on color Doppler ultrasonography: a specific feature of focal Hashimoto's thyroiditis. *Eur J Radiol* 81(11):3319-25 (2012)  
DOI: 10.1016/j.ejrad.2012.04.033
36. Fu XS, Li ZQ, Zhang HB, Wang JR: Sonographic features of focal Hashimoto's thyroiditis. *Zhongguo Yi Xue Ke Xue Yuan Xue Bao* 36(3):291-5 (2014)

37. Thomas T, Sreedharan S, Khadilkar UN, Deviprasad D, Kamath MP, Bhojwani KM, Alva A: Clinical, biochemical & cytomorphologic study on Hashimoto's thyroiditis. *Indian J Med Res* 140(6):729-35 (2014)
38. Wu H, Zhang B: Ultrasonographic appearance of focal Hashimoto's thyroiditis: A single institution experience. *Endocr J* 62(7):655-63 (2015)  
DOI: 10.1507/endocrj.EJ15-0083
39. Onoda N, Kato Y, Seki T, Kurimoto M, Takano K, Ito Y, Sato K: Increased thyroid blood flow in the hypoechoic lesions in patients with recurrent, painful Hashimoto's thyroiditis at the time of acute exacerbation. *Endocr J* 56(1):65-72 (2009)  
DOI: 10.1507/endocrj.K08E-194
40. Mousa U, Cunejd A, Alptekin G: Should neck pain in a patient with Hashimoto's thyroiditis be underestimated? A case and review of the literature. *Indian J Endocrinol Metab* 16(3):444-6 (2012)  
DOI: 10.4103/2230-8210.95709
41. Su DH, Liao KM, Hsiao YL, Chang TC: Determining when to operate on patients with Hashimoto's thyroiditis with nodular lesions: the role of ultrasound-guided fine needle aspiration cytology. *Acta Cytol* 48(5):622-9 (2004)  
DOI: 10.1159/000326432
42. Paksoy N, Yazal K: Cervical lymphadenopathy associated with Hashimoto's thyroiditis: an analysis of 22 cases by fine needle aspiration cytology. *Acta Cytol* 53(5):491-6 (2009)  
DOI: 10.1159/000325374
43. Luiz HV, Gonçalves D, Silva TN, Nascimento I, Ribeiro A, Mafra M, et al: IgG4-related Hashimoto's thyroiditis--a new variant of a well known disease. *Arq Bras Endocrinol Metabol* 58(8):862-8 (2014)  
DOI: 10.1590/0004-2730000003283
44. Vitti P, Rago T, Mazzeo S, Brogioni S, Lampis M, De Liperi A, et al: Thyroid blood flow evaluation by color-flow Doppler sonography distinguishes Graves' disease from Hashimoto's thyroiditis. *J Endocrinol Invest* 18(11):857-61 (1995)  
DOI: 10.1007/BF03349833
45. Anil C, Goksel S, Gursoy A: Hashimoto's thyroiditis is not associated with increased risk of thyroid cancer in patients with thyroid nodules: a single-center prospective study. *Thyroid* 20(6):601-6 (2010)  
DOI: 10.1089/thy.2009.0450
46. Chen J, Wang J: Diagnosis and surgical treatment of Hashimoto's thyroiditis complicated with papillary thyroid carcinoma (with 51 cases of clinical analysis) *Lin Chung Er Bi Yan Hou Tou Jing Wai Ke Za Zhi* 24(6):257-60 (2010)
47. Nabi J: Neurofibromatosis Type 1 Associated with Hashimoto's Thyroiditis: Coincidence or Possible Link. *Case Rep Neurol Med* 2013:910656 (2013)  
DOI: 10.1155/2013/910656
48. Adamczewski Z, Stasiołek M, Dedecjus M, Smolewski P, Lewiński A: Flow cytometry in the differential diagnostics of Hashimoto's thyroiditis and MALT lymphoma of the thyroid. *Endokrynol Pol* 66(1):73-8 (2015)  
DOI: 10.5603/EP.2015.0001
49. González-Colunga KJ, Loya-Solis A, Ceceñas-Falcón LÁ, Barboza-Quintana O, Rodríguez-Gutiérrez R: Warthin-Like Papillary Thyroid Carcinoma Associated with Lymphadenopathy and Hashimoto's Thyroiditis. *Case Rep Endocrinol* 2015:251898 (2015)  
DOI: 10.1155/2015/251898
50. Chen CC, Chen WC, Peng SL, Huang SM: Diffuse sclerosing variant of thyroid papillary carcinoma: diagnostic challenges occur with Hashimoto's thyroiditis. *J Formos Med Assoc* 112(6):358-62 (2013)  
DOI: 10.1016/j.jfma.2012.07.020
51. Matesa-Anić D, Matesa N, Dabelić N, Kusić Z: Coexistence of papillary carcinoma and Hashimoto's thyroiditis. *Acta Clin Croat* 48(1):9-12 (2009)
52. Popławska-Kita A, Telejko B, Siewko K, Kościuszko-Zdrodowska M, Wawrusiewicz-Kurylonek N, Krętowski A, et al: Decreased Expression of Thyroglobulin and Sodium Iodide Symporter Genes in Hashimoto's Thyroiditis. *Int J Endocrinol* 2014:690704 (2014)  
DOI: 10.1155/2014/690704
53. Savli H, Sevinc A, Sari R, Ozen S, Buyukberber S, Ertas E: Occult parathyroid carcinoma in a patient with papillary thyroid carcinoma and Hashimoto's thyroiditis. *J Endocrinol Invest* 24(1):42-4 (2001)

DOI: 10.1007/BF03343807

54. Boi F, Piga M, Loy M, Mariotti S: Hypothyroid Hashimoto's thyroiditis with scintigraphic and echo-color Doppler features mimicking autonomous adenoma. *J Endocrinol Invest* 25(5):469-72 (2002)  
DOI: 10.1007/BF03344040
55. Cheng V, Brainard J, Nasr C: Co-occurrence of papillary thyroid carcinoma and primary lymphoma of the thyroid in a patient with long-standing Hashimoto's thyroiditis. *Thyroid* 22(6):647-50 (2012)  
DOI: 10.1089/thy.2011.0228
56. Liu BJ, Xu HX, Zhang YF, Xu JM, Li DD, *et al*: Acoustic radiation force impulse elastography for differentiation of benign and malignant thyroid nodules with concurrent Hashimoto's thyroiditis. *Med Oncol* 32(3):50 (2015)  
DOI: 10.1007/s12032-015-0502-5
57. D'Onofrio M, Gallotti A, PozziMucelli R: Virtual Touch tissue quantification: measurement repeatability and normal values in the healthy liver. *AJR Am J Roentgenol* 195:132-136 (2010)  
DOI: 10.2214/AJR.09.3923
58. Gallotti A, D'Onofrio M, PozziMucelli R: Acoustic radiation force impulse (ARFI) technique in ultrasound with virtual touch tissue quantification of the upper abdomen. *Radiol Med* 115:889-897 (2010)  
DOI: 10.1007/s11547-010-0504-5
59. Han R, Li F, Wang Y, Ying Z, Zhang Y: Virtual touch tissue quantification (VTQ) in the diagnosis of thyroid nodules with coexistent chronic autoimmune Hashimoto's thyroiditis: a preliminary study. *Eur J Radiol* 84(2):327-31 (2015)  
DOI: 10.1016/j.ejrad.2014.11.005
60. Zhao RN, Zhang B, Yang X, Jiang YX, Lai XJ, Zhu SL, Zhang XY: Diagnostic value of contrast-enhanced ultrasound of thyroid nodules coexisting with hashimoto's thyroiditis. *Zhongguo Yi Xue Ke Xue Yuan Xue Bao* 37(1):66-70 (2015)

**Abbreviations:** ARFI: Acoustic radiation force impulse; VTQ: virtual touch tissue quantification

**Key Words:** Ultrasonography, Hashimoto's Thyroiditis, Diagnosis, Review

**Send correspondence to:** Guihua Wu, Department of B-Ultrasonic, Suzhou Wuzhong Peoples's Hospital, 61 Dongwu North Road, Wuzhong New Area, Suzhou 215128, China, Tel: 86-13013805486, Fax: 86-512-65252659, E-mail: wuguihua70@yeah.net